

---

# Breast Cancer Early Detection and Diagnosis

Breast cancer is sometimes found after symptoms appear, but many women with breast cancer have no symptoms. This is why regular breast cancer screening is so important. Learn more.

## Can Breast Cancer Be Found Early?

Breast cancer is sometimes found after symptoms appear, but many women with breast cancer have no symptoms. This is why regular breast cancer screening is so important. Learn more.

- [American Cancer Society Recommendations for the Early Detection of Breast Cancer](#)

## Imaging Tests to Find Breast Cancer

Different tests can be used to look for and diagnose breast cancer. If your doctor finds an area of concern on a screening test (a mammogram), or if you have symptoms that could mean breast cancer, you will need more tests to know for sure if it's cancer.

- [Mammograms](#)
- [Breast Ultrasound](#)
- [Breast MRI](#)
- [Newer and Experimental Breast Imaging Tests](#)

## Signs and Symptoms of Breast Cancer

The most common symptom of breast cancer is a new lump or mass, but other symptoms are also possible. It's important to have any breast change checked by a health care provider.

- [Breast Cancer Signs and Symptoms](#)

## Biopsy

A biopsy is done when mammograms, other imaging tests, or a physical exam shows a breast change that may be cancer. A biopsy is the only way to know for sure if it's cancer.

- [Breast Biopsy](#)

## Finding breast cancer during pregnancy

Breast cancer during pregnancy is rare. But if you find a lump or notice any unusual changes in your breasts that concern you, tell your doctor or nurse right away.

- [Finding Breast Cancer During Pregnancy](#)

---

# American Cancer Society Recommendations for the Early Detection of Breast Cancer

- [What are screening tests?](#)
- [American Cancer Society screening recommendations for women at average breast cancer risk](#)
- [American Cancer Society screening recommendations for women at high risk](#)

Finding breast cancer early and getting state-of-the-art cancer treatment are two of the most important strategies for preventing deaths from breast cancer. Breast cancer that's found early, when it's small and has not spread, is easier to treat successfully. Getting regular screening tests is the most reliable way to find breast cancer early. The American Cancer Society has screening guidelines for women at average risk of breast cancer, and for those at high risk for breast cancer.

## What are screening tests?

**Screening** refers to tests and exams used to find a disease in people who don't have any symptoms. The goal of screening tests for breast cancer is to find it early, before it causes symptoms (like a lump in the breast that can be felt). **Early detection** means finding and diagnosing a disease earlier than if you'd waited for symptoms to start.

Breast cancers found during screening exams are more likely to be smaller and less likely to have spread outside the breast. The size of a breast cancer and how far it has spread are some of the most important factors in predicting the **prognosis** (outlook) of a woman with this disease.

## American Cancer Society screening recommendations for women at average breast cancer risk

These guidelines are for women at **average risk** for breast cancer. For screening purposes, a woman is considered to be at average risk if she doesn't have a personal history of breast cancer, a strong family history of breast cancer, or a genetic mutation known to increase risk of breast cancer (such as in a *BRCA* gene), and has not had chest radiation therapy before the age of 30. (See below for guidelines for women at high risk.)

- **Women between 40 and 44** have the option to start screening with a mammogram every year.
- **Women 45 to 54** should get mammograms every year.
- **Women 55 and older** can switch to a mammogram every other year, or they can choose to continue yearly mammograms. Screening should continue as long as a woman is in good health and is expected to live at least 10 more years.
- **All women** should understand what to expect when getting a mammogram for breast cancer screening – what the test can and cannot do.

Clinical breast exams are not recommended for breast cancer screening among average-risk women at any age.

## Mammograms

[Mammograms](#) are low-dose x-rays of the breast. Regular mammograms can help find breast cancer at an early stage, when treatment is most likely to be successful. A mammogram can often find breast changes that could be cancer years before physical

symptoms develop. Results from many decades of research clearly show that women who have regular mammograms are more likely to have breast cancer found earlier, are less likely to need aggressive treatments like surgery to remove the entire breast ([mastectomy](#)<sup>1</sup>) and [chemotherapy](#)<sup>2</sup>, and are more likely to be cured.

Mammograms are not perfect. They miss some breast cancers. And if something is found on a screening mammogram, a woman will likely need other tests (such as more mammograms or a [breast ultrasound](#)) to find out if it is cancer. There's also a small chance of being diagnosed with a cancer that never would have caused any problems had it not been found during screening. (This is called *overdiagnosis*.) It's important that women getting mammograms know what to expect and understand the benefits and limitations of screening.

### **2D vs. 3D mammograms**

In recent years, a newer type of mammogram called [digital breast tomosynthesis](#) (commonly known as **three-dimensional [3D] mammography**) has become much more common, although it's not available in all breast imaging centers.

Many studies have found that 3D mammography appears to lower the chance of being [called back](#) after screening for follow-up testing. It also appears to find more breast cancers, and several studies have shown it can be helpful in women with more dense breasts. A large study is now in progress to better compare outcomes between 3D mammograms and standard (2D) mammograms.

It should be noted that 3D mammograms often cost more than 2D mammograms, and this added cost may not be covered by insurance.

The American Cancer Society (ACS) breast cancer screening guidelines consider having had either a 2D or 3D mammogram as being in line with current screening recommendations. The ACS also believes that women should be able to choose between 2D and 3D mammography if they or their doctor believes one would be more appropriate, and that out-of-pocket costs should not be a barrier to having either one.

### **Clinical breast exam (CBE) and breast self-exam (BSE)**

Research has not shown a clear benefit of regular physical breast exams done by either a health professional (clinical breast exams) or by women themselves (breast self-exams). There is very little evidence that these tests help find breast cancer early when women also get screening mammograms. Most often when breast cancer is detected because of [symptoms](#) (such as a lump in the breast), a woman discovers the symptom

during usual activities such as bathing or dressing. **Women should be familiar with how their breasts normally look and feel and should report any changes to a health care provider right away.**

While the American Cancer Society does not recommend regular clinical breast exams or breast self-exams as part of a routine breast cancer screening schedule, this does not mean that these exams should never be done. In some situations, particularly for women at higher-than-average risk, for example, health care providers may still offer clinical breast exams, along with providing counseling about risk and early detection. And some women might still be more comfortable doing regular self-exams as a way to keep track of how their breasts look and feel. But it's important to understand that there is very little evidence that doing these exams routinely is helpful for women at average risk of breast cancer.

## American Cancer Society screening recommendations for women at high risk

Women who are at **high risk** for breast cancer based on certain factors should get a [breast MRI](#) and a mammogram every year, typically starting at age 30. This includes women who:

- Have a lifetime risk of breast cancer of about 20% to 25% or greater, according to risk assessment tools that are based mainly on family history (see below)
- Have a known [BRCA1 or BRCA2 gene mutation](#)<sup>3</sup> (based on having had [genetic testing](#)<sup>4</sup>)
- Have a first-degree relative (parent, brother, sister, or child) with a *BRCA1* or *BRCA2* gene mutation, and have not had genetic testing themselves
- Had radiation therapy to the chest when they were between the ages of 10 and 30 years
- Have Li-Fraumeni syndrome, Cowden syndrome, or Bannayan-Riley-Ruvalcaba syndrome, or have first-degree relatives with one of these syndromes

The American Cancer Society recommends against MRI screening for women whose lifetime risk of breast cancer is less than 15%.

There's not enough evidence to make a recommendation for or against yearly MRI screening for women who have a higher lifetime risk based on certain factors, such as:

- Having a personal history of breast cancer, [ductal carcinoma in situ \(DCIS\)](#)<sup>5</sup>, [lobular](#)

[carcinoma in situ \(LCIS\)](#)<sup>6</sup>, [atypical ductal hyperplasia \(ADH\)](#), or [atypical lobular hyperplasia \(ALH\)](#)<sup>7</sup>

- Having “extremely” or “heterogeneously” **dense breasts** as seen on a mammogram

If MRI is used, it should be in addition to, not instead of, a screening mammogram. This is because although an MRI is more likely to find cancer than a mammogram, it may still miss some cancers that a mammogram would find.

Most women at high risk should begin screening with MRI and mammograms when they are 30 and continue for as long as they are in good health. But this is a decision that should be made with a woman's health care providers, taking into account her personal circumstances and preferences.

### **Tools used to assess breast cancer risk**

Several risk assessment tools can help health professionals estimate a woman's breast cancer risk. These tools give rough estimates of breast cancer risk, based on different combinations of risk factors and different data sets.

Because each of these tools uses different factors to estimate risk, they might give different risk estimates for the same woman. A woman's risk estimates can also change over time.

Risk assessment tools that include family history in first-degree relatives (parents, siblings, and children) and second-degree relatives (such as aunts and cousins) on both sides of the family should be used with the ACS guidelines to decide if a woman should have MRI screening. The use of any of the risk assessment tools and its results should be discussed by a woman with her health care provider.

### **Hyperlinks**

1. [www.cancer.org/cancer/types/breast-cancer/treatment/surgery-for-breast-cancer/mastectomy.html](http://www.cancer.org/cancer/types/breast-cancer/treatment/surgery-for-breast-cancer/mastectomy.html)
2. [www.cancer.org/cancer/types/breast-cancer/treatment/chemotherapy-for-breast-cancer.html](http://www.cancer.org/cancer/types/breast-cancer/treatment/chemotherapy-for-breast-cancer.html)
3. [www.cancer.org/cancer/types/breast-cancer/risk-and-prevention/breast-cancer-risk-factors-you-cannot-change.html](http://www.cancer.org/cancer/types/breast-cancer/risk-and-prevention/breast-cancer-risk-factors-you-cannot-change.html)

4. [www.cancer.org/cancer/types/breast-cancer/risk-and-prevention/genetic-testing.html](http://www.cancer.org/cancer/types/breast-cancer/risk-and-prevention/genetic-testing.html)
5. [www.cancer.org/cancer/types/breast-cancer/about/types-of-breast-cancer/dcis.html](http://www.cancer.org/cancer/types/breast-cancer/about/types-of-breast-cancer/dcis.html)
6. [www.cancer.org/cancer/types/breast-cancer/non-cancerous-breast-conditions/lobular-carcinoma-in-situ.html](http://www.cancer.org/cancer/types/breast-cancer/non-cancerous-breast-conditions/lobular-carcinoma-in-situ.html)
7. [www.cancer.org/cancer/types/breast-cancer/non-cancerous-breast-conditions/hyperplasia-of-the-breast-ductal-or-lobular.html](http://www.cancer.org/cancer/types/breast-cancer/non-cancerous-breast-conditions/hyperplasia-of-the-breast-ductal-or-lobular.html)

## References

Oeffinger KC, Fontham ET, Etzioni R, et al. Breast cancer screening for women at average risk: 2015 guideline update From the American Cancer Society. *JAMA*. 2015;314(15):1599-1614.

Saslow D, Boetes C, Burke W, et al. American Cancer Society guidelines for breast screening with MRI as an adjunct to mammography. *CA Cancer J Clin*. 2007 Mar-Apr;57(2):75-89.

Last Revised: January 14, 2022

---

# Mammograms

Mammograms are low-dose x-rays that can help find breast cancer. If you've been told you need a mammogram, or you're ready to start breast cancer screening, the topics below can help you know what to expect.

## [Getting a mammogram](#)

Find out what a mammogram is, why it's done, what doctors look for, and what it's like to get one.

- [Mammogram Basics](#)

- [Tips for Getting a Mammogram](#)
- [What Does the Doctor Look for on a Mammogram?](#)
- [Getting Called Back After a Mammogram](#)

### [Understanding your results](#)

Doctors use a standard system called the Breast Imaging Reporting and Data System (BI-RADS) to describe what they see on a mammogram. Learn how to understand your results, and what it means if your mammograms show dense breast tissue.

- [Understanding Your Mammogram Report](#)
- [Breast Density and Your Mammogram Report](#)
- [Limitations of Mammograms](#)

### [Mammograms in special circumstances](#)

If you have had breast cancer in the past, whether or not you need to keep getting mammograms might depend on the type of surgery you had. If you have breast implants, you can and should get mammograms as recommended. But you might need to have extra pictures taken so the doctor can see as much breast tissue as possible.

- [Mammograms After Breast Cancer Surgery](#)
- [Mammograms for Women with Breast Implants](#)

Last Revised: January 14, 2022

---

## Mammogram Basics

- [Why do I need mammograms?](#)
- [What are the main uses of mammograms?](#)
- [What do mammograms show?](#)
- [How do mammograms work?](#)
- [What are three-dimensional \(3D\) mammograms?](#)
- [Are mammograms safe?](#)

A mammogram is a low-dose x-ray that allows doctors called *radiologists* to look for changes in breast tissue.



## Why do I need mammograms?

Mammograms can be used to look for breast cancer, either as a screening test in women without symptoms or in women who have [symptoms that might be from cancer](#). A mammogram can often find or detect breast cancer early, when it's small and even before a lump can be felt. This is when it's likely to be easiest to treat.

## What are the main uses of mammograms?

### Screening mammograms

A **screening mammogram** is used to look for signs of breast cancer in women who don't have any breast symptoms or problems. X-ray pictures of each breast are taken, typically from 2 different angles.

### Diagnostic mammograms

Mammograms are used to look at a woman's breast if she has breast symptoms or if something unusual is seen on a screening mammogram. When used in this way, they are called **diagnostic mammograms**. They may include extra views (images) of the breast that aren't part of screening mammograms. Sometimes diagnostic mammograms are used to screen women who were treated for breast cancer in the past.

## What do mammograms show?

Mammograms can often show abnormal areas in the breast. They can't tell for sure if an abnormal area is cancer, but they can help health care providers decide if more testing (such as a breast biopsy) is needed. The main types of breast changes found with a mammogram are:

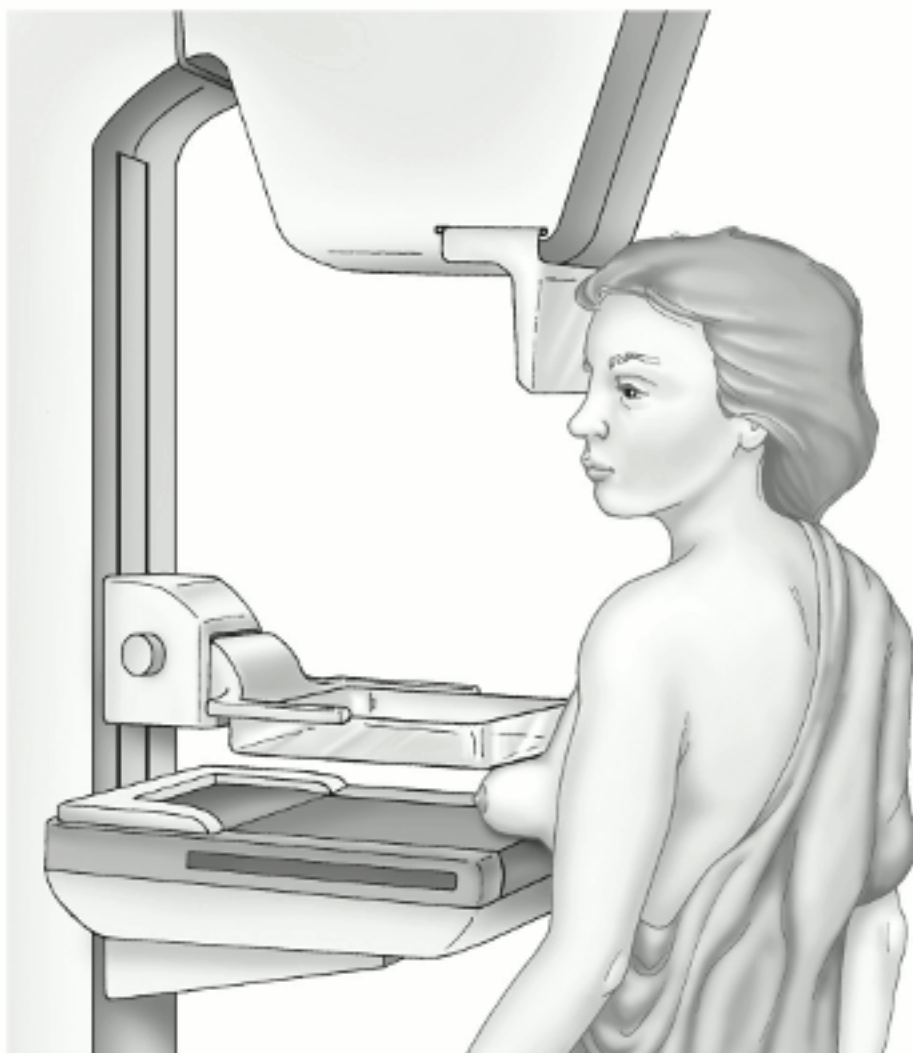
- Calcifications
- Masses
- Asymmetries
- Distortions

Learn more about these and other breast changes in [What Does the Doctor Look for on a Mammogram?](#)

## How do mammograms work?

Mammograms are done with a machine designed to look only at breast tissue. The machine takes x-rays at lower doses than the x-rays done to look at other parts of the body, like the lungs or bones. The mammogram machine has 2 plates that compress or flatten the breast to spread the tissue apart. This gives a better quality picture and allows less radiation to be used.

To learn more about how they are done, see [Tips for Getting a Mammogram](#).



© Sam and Amy Collins

## Mammogram

In the past, mammograms were typically printed on large sheets of film. Today, **digital mammograms** are much more common. Digital images are recorded and saved as files in a computer.

## What are three-dimensional (3D) mammograms?

Three-dimensional (3D) mammography is also known as **breast tomosynthesis** or **digital breast tomosynthesis (DBT)**. As with a standard (2D) mammogram, each breast is compressed from two different angles (once from top to bottom and once from side to side) while x-rays are taken. But for a 3D mammogram, the machine takes many low-dose x-rays as it moves in a small arc around the breast. A computer then puts the images together into a series of thin slices. This allows doctors to see the breast tissues more clearly in three dimensions. (A standard two-dimensional [2D] mammogram can be taken at the same time, or it can be reconstructed from the 3D mammogram images.)

Many studies have found that 3D mammography appears to lower the chance of being [called back](#) for follow-up testing after screening. It also appears to find more breast cancers, and several studies have shown it can be helpful in women with [dense breasts](#). A large study is now in progress to better compare outcomes between 3D mammograms and standard (2D) mammograms.

For more on 3D mammograms, see [American Cancer Society Recommendations for the Early Detection of Breast Cancer](#).

## Are mammograms safe?

Mammograms expose the breasts to small amounts of radiation. But the benefits of mammography outweigh any possible harm from the [radiation exposure](#)<sup>1</sup>. Modern machines use low radiation doses to get breast x-rays that are high in image quality. On average the total dose for a typical mammogram with 2 views of each breast is about 0.4 millisieverts, or mSv. (A mSv is a measure of radiation dose.) The radiation dose from 3D mammograms can range from slightly lower to slightly higher than that from standard 2D mammograms.

To put these doses into perspective, people in the US are normally exposed to an average of about 3 mSv of radiation each year just from their natural surroundings. (This is called *background radiation*.) The dose of radiation used for a screening mammogram of both breasts is about the same amount of radiation a woman would get from her natural surroundings over about 7 weeks.

If there's any chance you might be [pregnant](#), let your health care provider and x-ray technologist know. Although the risk to the fetus is very small, and mammograms are generally thought to be safe during pregnancy, screening mammograms aren't routinely done in pregnant women who aren't at increased risk for breast cancer.

Mammograms might also result in some women getting additional tests that don't result in a breast cancer diagnosis, but that might still have their own harms. For more on this, see [Limitations of Mammograms](#).

## Hyperlinks

1. [www.cancer.org/cancer/risk-prevention/radiation-exposure/x-rays-gamma-rays.html](http://www.cancer.org/cancer/risk-prevention/radiation-exposure/x-rays-gamma-rays.html)

## References

Bahl M, Pinnamaneni N, Mercaldo S, et al. Digital 2D versus tomosynthesis screening mammography among women aged 65 and older in the United States. *Radiology*. 2019; 291:582-590.

Helvie MA, Patterson SK. Chapter 11: Imaging Analysis: Mammography. In: Harris JR, Lippman ME, Morrow M, Osborne CK, eds. *Diseases of the Breast*. 5th ed. Philadelphia, Pa: Lippincott Williams & Wilkins; 2014.

Hendrick RE. Radiation doses and cancer risks from breast imaging studies. *Radiology*. 2010;257(1):246-253.

Lowry KP, Coley RY, Miglioretti DL, et al. Screening performance of digital breast tomosynthesis vs digital mammography in community practice by patient age, screening round, and breast density. *JAMA Netw Open*. 2020;3(7):e2011792.

Oeffinger KC, Fontham ET, Etzioni R, et al. Breast cancer screening for women at average risk: 2015 guideline update from the American Cancer Society. *JAMA*. 2015;314(15):1599-614.

Puliti D, Duffey SW, Miccinesi G, et al. Overdiagnosis in mammographic screening for breast cancer in Europe: A literature review. *J Med Screen*, 2012;19:Suppl 1:42-56.

Radiological Society of North America (RSNA). Breast Tomosynthesis. 2020. Accessed at <https://www.radiologyinfo.org/en/info/tomosynthesis> on September 28, 2021.

Radiological Society of North America (RSNA). Radiation Dose in X-Ray and CT Exams. 2019. Accessed at <https://www.radiologyinfo.org/en/info/safety-xray> on September 28, 2021.

Rose SL, Tidwell AL, Bujnoch LJ, et al. Implementation of breast tomosynthesis in a routine screening practice: An observational study. *AJR Am J Roentgenol*. 2013;200(6):1401-1408.

Skaane P, Bandos AI, Gullien R, et al. Comparison of digital mammography alone and digital mammography plus tomosynthesis in a population-based screening program. *Radiology*. 2013;267(1):47-56.

Svahn TM, Houssami N, Sechopoulos I, Mattsson S. Review of radiation dose estimates in digital breast tomosynthesis relative to those in two-view full-field digital mammography. *Breast*. 2015;24(2):93-99.

Last Revised: January 14, 2022

## Tips for Getting a Mammogram

- [How to prepare for your mammogram](#)
- [What to tell your technologist](#)
- [What to expect when getting a screening mammogram](#)
- [What to expect when getting a diagnostic mammogram](#)
- [How will I get my mammogram results?](#)

A mammogram is an important step in taking care of yourself and your breasts. Whether you're a mammogram newbie or a veteran, knowing what to expect may help the process go more smoothly.

### How to prepare for your mammogram

- If you have a choice, go to a facility that specializes in mammograms and does many mammograms a day.
- Try to go to the same facility every time so that your mammograms can easily be compared from year to year.
- If you're going to a facility for the first time, bring a list of the places and dates of mammograms, biopsies, or any other breast procedures you've had before.
- If you've had mammograms at another facility, try to get those records to bring with you to the new facility (or have them sent there) so the old pictures can be

compared to the new ones.

- Schedule your mammogram for when your breasts aren't likely to be tender or swollen, to help reduce discomfort and get good pictures. Try to avoid the week just before your period.
- On the day of the exam, don't apply deodorant, antiperspirant, powders, lotions, creams, or perfumes under your arms, or on or under your breasts. Some of these contain substances that can show up on the x-ray as white spots. If you're not going home after your exam, you might want to take your deodorant or antiperspirant with you to put on after your exam. (Many centers will have cleaning and deodorant wipes to help you wipe off the deodorant and then replace it after the exam.)
- You might find it easier to wear a skirt or pants, so that you'll only need to remove your top and bra for the mammogram.
- Discuss any recent changes or problems in your breasts with your health care provider before getting the mammogram. (If you have symptoms, you may need a [diagnostic mammogram](#) so special images can be taken of the area of concern.)
- Make sure your provider is aware of any part of your medical history that could affect your breast cancer risk—such as surgery, hormone use, breast cancer in your family, or if you've had breast cancer before.

Don't be afraid of mammograms! Remember that only about 2 to 4 screening mammograms in 1,000 lead to a diagnosis of breast cancer.

## What to tell your technologist

To help ensure you have a good quality mammogram, make sure your technologist knows:

- About any breast changes or problems you're having
- If you have breast implants
- If you have trouble standing and holding still alone (without the aid of a cane or walker)
- If you're breastfeeding or if you think you might be pregnant.

Tell the technologist right away if you start feeling lightheaded or dizzy during the mammogram.

## What to expect when getting a screening mammogram

- You'll have to undress above the waist to get a mammogram. The facility will give you a wrap to wear.
- You and the technologist will be the only ones in the room during the mammogram.
- To get a high-quality picture, your breast must be flattened or compressed. You'll stand in front of the machine, and the technologist will place your breast on the machine. The plastic upper plate is then lowered to compress your breast for about 10 to 15 seconds while the technologist takes an x-ray. You will then need to change position so your breast is compressed from side to side before the next x-ray is taken.
- If you're getting a **3D mammogram** (also known as digital breast tomosynthesis, or DBT), the procedure is the same as above, but you'll notice that the machine will move in a small arc, either over the top of your breast or along the side of your breast, for each image. You might be asked to hold your breath each time it's being done.
- The whole procedure takes about 20 minutes. The actual breast compression only lasts about 10 to 15 seconds for each image.
- You might feel some discomfort when your breasts are compressed, and for some women it can be painful. Tell the technologist if it hurts so they can try to adjust the compression to your comfort.
- Two views of each breast are taken for a screening mammogram. But for some women, such as those with breast implants or larger breasts, more pictures may be needed.

## What to expect when getting a diagnostic mammogram

A diagnostic mammogram is often done if a woman has breast symptoms or if something unusual is seen on a screening mammogram. The basic procedure is similar to that for a screening mammogram, but there are some differences.

- More pictures are taken during a diagnostic mammogram, with a focus on the area that looked different on the screening mammogram (or where the symptoms are).
- These special images may be "spot views" or "magnification views," which are used to make the area of concern easier to see.
- Again, if a **3D mammogram** is being done, the procedure is the same, but you might be asked to hold your breath while the machine moves in a small arc around

your breast to create each image.

- During a diagnostic mammogram, the images are checked by the radiologist while you're there so that more pictures can be taken if needed to look more closely at any area of concern. (Depending on the findings, a [breast ultrasound](#) may also be done to look at the area of concern.)

## How will I get my mammogram results?

A full report of the results of your mammogram will be sent to your health care provider. **If you don't hear from your health care provider within 10 days, do not assume that your mammogram was normal.** Call your provider or the facility where the mammogram was done.

The mammography facility also must provide you with an easy-to-understand summary of your mammogram results within 30 days—or “as quickly as possible” if the results suggest something abnormal is present. If you have online access to your medical records, such as through a patient portal, your results might show up there at the same time your health care provider gets them. This means you could get the results before your health care provider contacts you. Be sure to go over the results with your provider, especially if there's anything you don't understand.

We can help you learn more about [how to understand your mammogram report](#).

## References

Helvie MA, Patterson SK. Chapter 11: Imaging Analysis: Mammography. In: Harris JR, Lippman ME, Morrow M, Osborne CK, eds. *Diseases of the Breast*. 5th ed. Philadelphia, Pa: Lippincott Williams & Wilkins; 2014.

Radiological Society of North America (RSNA). Mammography. 2021. Accessed at <https://www.radiologyinfo.org/en/info/mammo> on September 29, 2021.

Rosenberg RD, Hunt WC, Williamson MR, et al. Effects of age, breast density, ethnicity, and estrogen replacement therapy on screening mammographic sensitivity and cancer stage at diagnosis: Review of 183,134 screening mammograms in Albuquerque, New Mexico. *Radiology* 1998;209:511–518.

US Food and Drug Administration. Direct-to-Patient Mammogram Results: It's the Law.



2018. Accessed at <https://www.fda.gov/radiation-emitting-products/mqsa-insights/direct-patient-mammogram-results-its-law> on September 29, 2021.

Last Revised: January 14, 2022

## What Does the Doctor Look for on a Mammogram?

- [Calcifications](#)
- [Masses](#)
- [Asymmetries](#)
- [Architectural distortion](#)
- [Breast density](#)

A radiologist will look at your mammogram. Radiologists are doctors who diagnose diseases and injuries using imaging tests such as x-rays.

When possible, the doctor reading your mammogram will compare it to your old mammograms. This can help show if any findings are new, or if they were already there on previous mammograms. Findings that haven't changed from older mammograms aren't likely to be cancer, which might mean you won't need further tests.

The doctor reading your mammogram will be looking for different types of breast changes, such as small white spots called *calcifications*, abnormal areas called *masses*, and other suspicious findings that could be signs of cancer.

### Calcifications

Calcifications are tiny calcium deposits within the breast tissue. They look like small white spots on a mammogram. They may or may not be caused by cancer. There are 2 types of calcifications.

#### Macrocalcifications

Macrocalcifications are larger calcium deposits that are most likely due to changes

caused by aging of the breast arteries, old injuries, or inflammation. These deposits are typically related to non-cancerous conditions and don't need further testing with a [biopsy](#). Macrocalcifications become more common as women get older (especially after age 50).

## Microcalcifications

Microcalcifications are tiny specks of calcium in the breast. When seen on a mammogram, they are more of a concern than macrocalcifications, but they don't always mean that cancer is present. The shape and layout of microcalcifications (and whether they are near a mass) help the radiologist judge how likely it is that the change is due to cancer.

In most cases, microcalcifications don't need to be checked with a biopsy. But if they have a suspicious look and pattern, a biopsy will be recommended to check for cancer.

## Masses

A mass is an area of abnormal breast tissue with a shape and edges that make it look different than the rest of the breast tissue on a mammogram. A mass might be seen with or without calcifications. Masses can be many things, including [cysts](#)<sup>1</sup> (non-cancerous, fluid-filled sacs) and non-cancerous solid tumors (such as [fibroadenomas](#)<sup>2</sup>), but they may also be a sign of cancer.

**Cysts** are fluid-filled sacs. Simple cysts (fluid-filled sacs with thin walls) are not cancer and typically don't need to be checked with a biopsy. If a mass is not a simple cyst, it's of more concern, so a biopsy might be needed to be sure it isn't cancer.

**Solid masses** can be more concerning, but most solid breast masses are not cancer.

A cyst and a solid mass can feel the same. They can also sometimes look the same on a mammogram. The doctor must be sure it's a cyst to know it's not cancer, so a [breast ultrasound](#) is often done (because it is better than a mammogram at showing if the inside of a mass is solid or filled with fluid).

If it isn't clear if the mass is a cyst or a solid mass, a [thin, hollow needle](#) may be inserted into the mass during an ultrasound to try to remove (aspirate) the fluid from the area. If the mass goes away on the ultrasound as the fluid is removed, then it is most likely a cyst and no further work up is needed.

If a mass is not a simple cyst (that is, if it's at least partly solid, or if it has other

concerning features), more [imaging tests](#) might be needed to decide if it could be cancer. Some masses can be watched over time with regular mammograms or ultrasound to see if they change, but others may need to be checked with a biopsy. The size, shape, and margins (edges) of the mass can help the radiologist decide [how likely it is to be cancer](#).

## Asymmetries

Asymmetries are white areas seen on a mammogram that look different from the normal breast tissue pattern. There are different types of asymmetries, including focal asymmetry, developing asymmetry, and global asymmetry.

Most of the time, these findings do not mean you have breast cancer. But more imaging tests will likely be needed to make sure there is no cancer in this area.

## Architectural distortion

Radiologists use this term to describe when an area of the breast tissue appears distorted or pulled toward a certain point. Sometimes this may just be due to how the breast was positioned during the mammogram. It might also be caused by a prior injury or procedure done on the breast. But architectural distortion can also sometimes be a sign of a breast cancer, so further imaging with [diagnostic mammograms](#) is typically needed to get a better look at this area.

## Breast density

Your mammogram report will also contain an assessment of your [breast density](#). Breast density is a measure of how much fibrous and glandular tissue is in your breast, compared to fatty tissue. It isn't related to breast size or firmness.

Your breast tissue may be called 'dense' if you have more fibrous and glandular tissue compared to fatty tissue in the breast.

About half of all women have dense breasts. Having dense breasts is not abnormal. However, women who have dense breasts have a slightly higher risk of breast cancer.

Dense breast tissue can also make it harder to see cancers on a mammogram. This is because fibrous and glandular tissue appear white on a mammogram, which can hide many types of suspicious findings that also appear white. Still, experts don't agree what other tests, if any, should be done along with mammograms in women with dense

breasts who aren't otherwise at higher risk for breast cancer (based on gene mutations, breast cancer in the family, or other factors).

## Hyperlinks

1. [www.cancer.org/cancer/types/breast-cancer/non-cancerous-breast-conditions/fibrosis-and-simple-cysts-in-the-breast.html](http://www.cancer.org/cancer/types/breast-cancer/non-cancerous-breast-conditions/fibrosis-and-simple-cysts-in-the-breast.html)
2. [www.cancer.org/cancer/types/breast-cancer/non-cancerous-breast-conditions/fibroadenomas-of-the-breast.html](http://www.cancer.org/cancer/types/breast-cancer/non-cancerous-breast-conditions/fibroadenomas-of-the-breast.html)

## References

Esserman LJ, Joe BN. Diagnostic evaluation of suspected breast cancer. UpToDate. 2021. Accessed at <https://www.uptodate.com/contents/diagnostic-evaluation-of-suspected-breast-cancer> on September 29, 2021.

Helvie MA, Patterson SK. Chapter 11: Imaging Analysis: Mammography. In: Harris JR, Lippman ME, Morrow M, Osborne CK, eds. *Diseases of the Breast*. 5th ed. Philadelphia, Pa: Lippincott Williams & Wilkins; 2014.

Venkataraman S, Slanetz PJ, Lee CI. Breast imaging for cancer screening: Mammography and ultrasonography. UpToDate. 2021. Accessed at <https://www.uptodate.com/contents/breast-imaging-for-cancer-screening-mammography-and-ultrasonography> on September 29, 2021.

Last Revised: January 14, 2022

---

# Getting Called Back After a Mammogram

- [Why might I be called back?](#)
- [What will happen at the follow-up appointment?](#)

- [What if I need a biopsy?](#)
- [How can I stay calm while waiting?](#)
- [What if it's cancer?](#)

Getting called back after a screening mammogram is fairly common, and it doesn't mean you have breast cancer. In fact, fewer than 1 in 10 women called back for more tests are found to have cancer. Often, it just means more mammograms or other tests (such as an [ultrasound](#)) need to be done to get a closer look at an area of concern.

If you do need more tests, ask your doctor about how quickly these tests can be scheduled. This can vary based on a number of factors, such as how busy the testing centers are in your area.

Getting called back is more common after a first mammogram, or when there's no previous mammogram to compare to the new mammogram. It's also more common in women who haven't gone through menopause.

## Why might I be called back?

You could be called back after your mammogram because:

- The pictures weren't clear or didn't show some of your breast tissue, so they need to be retaken.
- The radiologist (doctor who reads the mammogram) sees something suspicious, such as [calcifications or a mass](#) (which could be a [cyst](#)<sup>1</sup> or solid mass).
- The radiologist sees an area that just looks different from other parts of the breast.

Sometimes when more mammograms are taken of an abnormal-looking area, or the area is compressed more, it no longer looks suspicious. In fact, most often the additional images show the finding isn't cancer.

## What will happen at the follow-up appointment?

- You'll likely get another mammogram called a *diagnostic mammogram*. (Your previous mammogram was called a *screening mammogram*.) A diagnostic mammogram is done just like a screening mammogram, but more pictures are taken so that any areas of concern can be looked at more closely. A doctor called a radiologist will be on hand to advise the technologist (the person who operates the

mammogram machine), to be sure they have all the images that are needed.

- You may also get another imaging test, such as an [ultrasound of the breast](#), which uses sound waves to make pictures of the inside of your breast at the area of concern.

You will most likely be given the results of your tests during the visit. You might be told one of the following:

- The suspicious area on the mammogram turned out to be nothing to worry about, and you can return to your normal mammogram schedule.
- The area is probably nothing to worry about, but you should have your next imaging test (mammogram and/or ultrasound) sooner than normal – usually in about 6 months – to watch the area closely and make sure it's not changing over time.
- The area could be cancer, so you will need a biopsy (see below) to know for sure.

You'll also get a letter with a summary of the findings that will tell you if you need more tests and/or when you should schedule your next mammogram.

## What if I need a biopsy?

During a [breast biopsy](#), small pieces of breast tissue are removed and checked for cancer under a microscope. Even if you need a biopsy, it doesn't mean you have cancer. Most biopsy results are not cancer, but a biopsy is the only way to find out.

There are different types of breast biopsies, some of which are done using a [small, hollow needle](#) and some that are done [through a cut in the skin](#). The type you have depends on things like how suspicious the area looks, how big it is, where it is in the breast, other medical problems you might have, and your personal preferences.

## How can I stay calm while waiting?

Waiting for appointments and the results of tests can be frightening, especially if you were told the results of your first mammogram weren't normal. You might have strong emotions, such as disbelief, anxiety, fear, anger, or sadness during this time. Here are some things to remember:

- It's normal to have these feelings.
- Most often, breast changes are not cancer and are not life-threatening.

- Talking with a loved one or a counselor about your feelings may help.
- Talking with other women who have been called back after a mammogram may help.
- The American Cancer Society is available at 1-800-227-2345 around the clock to answer your questions and provide support.

## What if it's cancer?

If you do have breast cancer and you're referred to a breast specialist, use these tips to make your appointment as useful as possible:

- Make a [list of questions](#)<sup>2</sup> to ask.
- Take a family member or friend with you. They can serve as an extra pair of ears, take notes, help you remember things later, and give you support.
- Ask if you can record the conversations. You might also want to take notes.
- If someone uses a word you don't know, ask them to spell it and explain it.
- Ask the doctors or nurses to explain anything you don't understand.

## Hyperlinks

1. [www.cancer.org/cancer/types/breast-cancer/non-cancerous-breast-conditions/fibrosis-and-simple-cysts-in-the-breast.html](http://www.cancer.org/cancer/types/breast-cancer/non-cancerous-breast-conditions/fibrosis-and-simple-cysts-in-the-breast.html)
2. [www.cancer.org/cancer/managing-cancer/making-treatment-decisions/questions-to-ask-your-doctor.html](http://www.cancer.org/cancer/managing-cancer/making-treatment-decisions/questions-to-ask-your-doctor.html)

## References

Helvie MA, Patterson SK. Chapter 11: Imaging Analysis: Mammography. In: Harris JR, Lippman ME, Morrow M, Osborne CK, eds. *Diseases of the Breast*. 5th ed. Philadelphia, Pa: Lippincott Williams & Wilkins; 2014.

Last Revised: May 17, 2022

# Understanding Your Mammogram Report

- [What is a BI-RADS assessment category?](#)
- [What do the BI-RADS categories mean?](#)
- [BI-RADS reporting breast density](#)

A doctor called a **radiologist** will categorize your mammogram results using a numbered system. Talk to your doctor about your mammogram results and what you need to do next.

## What is a BI-RADS assessment category?

Doctors use a standard system to describe mammogram findings and results. This system (called the **Breast Imaging Reporting and Data System** or **BI-RADS**) sorts the results into categories numbered 0 through 6.

With these categories, doctors can describe what they find on a mammogram using the same words and terms. This makes communicating about the test results and following up after the tests easier.

(**Note:** These same BI-RADS categories can also be used to describe the results of a [breast ultrasound](#) or [breast MRI](#) exam. However, the recommended next steps after these tests might be slightly different.)

## What do the BI-RADS categories mean?

Category	Definition	What it means
0	Incomplete - Additional imaging evaluation and/or comparison to prior mammograms (or other imaging tests) is needed.	This means the radiologist may have seen a possible abnormality, but it is not clear and you will need more tests, such as another mammogram with use of spot compression (applying compression to a smaller area when taking the mammogram), magnified views, special mammogram views, and/or <a href="#">ultrasound</a> . This may also suggest that the radiologist wants to compare a new mammogram with older ones to see if there have been changes in that area over time.



1	Negative	This is a normal test result. Your breasts look the same (they are symmetrical) with no <b>masses (lumps), distorted structures, or suspicious calcifications</b> . In this case, <b>negative</b> means nothing new or abnormal was found.
2	Benign (non-cancerous) finding	This is also a negative test result (there's no sign of cancer), but the radiologist chooses to describe a finding that is not cancer, such as benign calcifications, masses, or lymph nodes in the breast. This can also be used to describe changes from a prior procedure (such as a biopsy) in the breast. This finding means that others who look at the mammogram in the future will not misinterpret the benign finding as suspicious.
3	Probably benign finding – Follow-up in a short time frame is suggested	A finding in this category has a very low (no more than 2%) chance of being cancer. It is not expected to change over time. But since it's not proven to be benign, it's helpful to be extra safe and see if the area in question changes over time.  You will likely need follow-up with repeat imaging in 6 to 12 months and then regularly after that until the finding is known to be stable (usually at least 2 years). This approach helps avoid unnecessary <b>biopsies</b> , but if the area does change over time, it still allows for early diagnosis.
4	Suspicious abnormality – Biopsy should be considered	These findings do not definitely look like cancer but could be cancer. The radiologist is concerned enough to recommend a <b>biopsy</b> . The findings in this category can have a wide range of suspicion levels. For this reason, this category is often divided further:  <b>4A:</b> Finding with a low likelihood of being cancer (more than 2% but not more than 10%)  <b>4B:</b> Finding with a moderate likelihood of being cancer (more than 10% but not more than 50%)  <b>4C:</b> Finding with a high likelihood of being cancer (more than 50% but not more than 95%), but not as high as Category 5
5	Highly suggestive of malignancy – Appropriate action should be taken	The findings look like cancer and have a high chance (at least 95%) of being cancer. Biopsy is very strongly recommended.
6	Known biopsy-proven malignancy – Appropriate action should be taken	This category is only used for findings on a mammogram (or ultrasound or MRI) that have already been shown to be cancer by a previous biopsy. This category may be used in this way to see how well the cancer is responding to treatment.

### BI-RADS reporting breast density

Your mammogram report will also include an assessment of your breast density, which is a description of how much fibrous and glandular tissue is in your breasts, as compared to fatty tissue. The denser your breasts, the harder it can be to see abnormal areas on mammograms. (Having dense breasts also slightly raises your risk of getting breast cancer.)

BI-RADS classifies breast density into 4 groups, which are described in [Breast Density and Your Mammogram Report](#).

## References

American College of Radiology. ACR BI-RADS ATLAS – Mammography. Reporting System, 2013. Accessed at <https://www.acr.org/-/media/ACR/Files/RADS/BI-RADS/Mammography-Reporting.pdf> on September 30, 2021.

Helvie MA, Patterson SK. Chapter 11: Imaging Analysis: Mammography. In: Harris JR, Lippman ME, Morrow M, Osborne CK, eds. *Diseases of the Breast*. 5th ed. Philadelphia, Pa: Lippincott Williams & Wilkins; 2014.

Venkataraman S, Slanetz PJ, Lee CI. Breast imaging for cancer screening: Mammography and ultrasonography. UpToDate. 2021. Accessed at <https://www.uptodate.com/contents/breast-imaging-for-cancer-screening-mammography-and-ultrasonography> on September 30, 2021.

Last Revised: January 14, 2022

---

# Breast Density and Your Mammogram Report

- [What is dense breast tissue?](#)
- [How do I know if I have dense breasts?](#)
- [Why is breast density important?](#)
- [If I have dense breasts, do I still need a mammogram?](#)
- [Should I have any other screening tests if I have dense breast tissue?](#)
- [What should I do if I have dense breast tissue?](#)

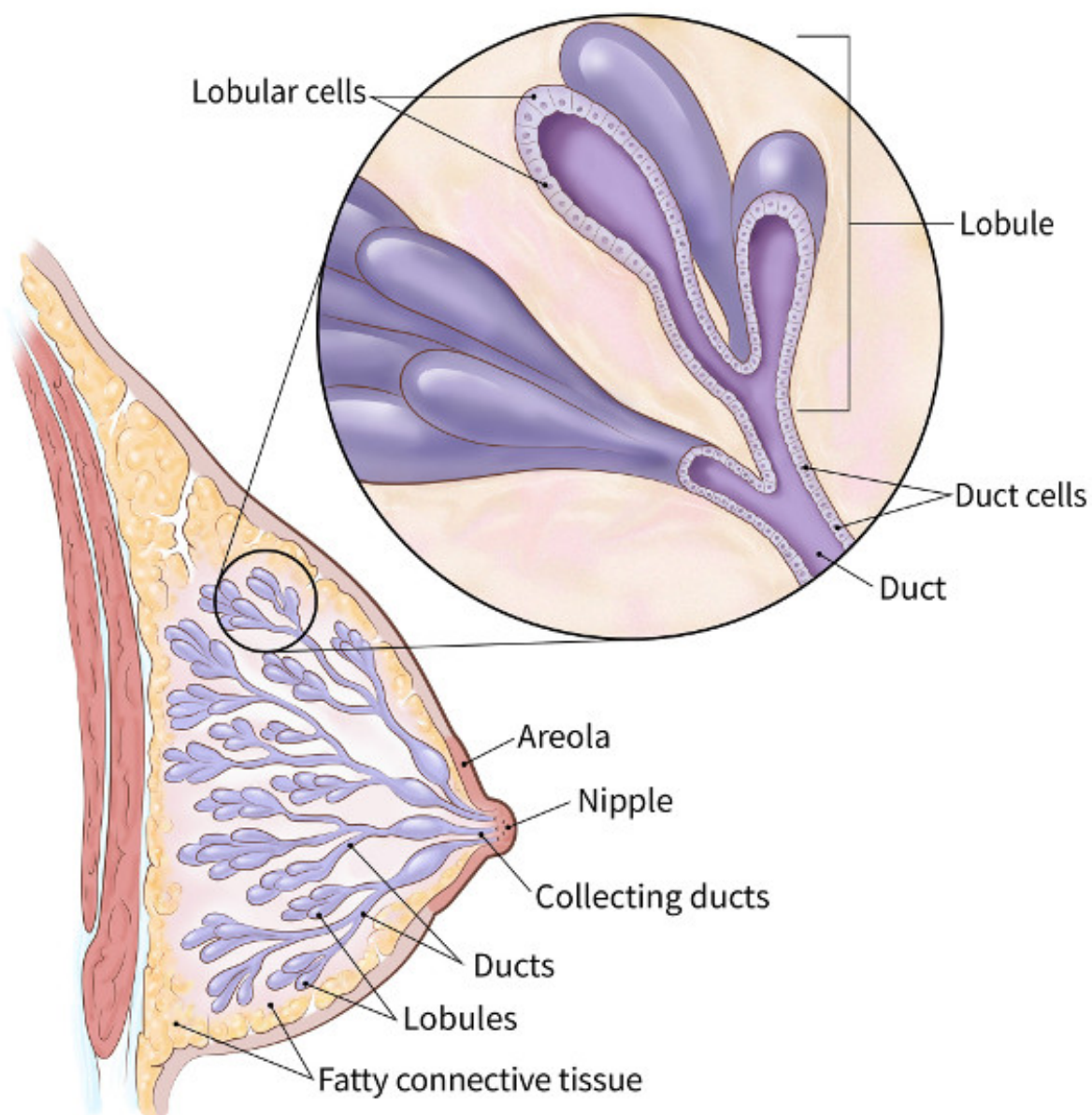
Regular mammograms are the best way to find breast cancer early. But if your mammogram report says that you have dense breast tissue, you may be wondering what that means.

## What is dense breast tissue?

Breast density is a measure of how much fibrous and glandular tissue (also known as *fibroglandular tissue*) there is in your breast, as compared to fat tissue. It isn't related to breast size or firmness.

Breasts are made up of lobules, ducts, and fatty and fibrous connective tissue.

- **Lobules** are the small glands that produce milk, while **ducts** are the tiny tubes that carry the milk from the lobules to the nipple. Together, the lobules and ducts are referred to as **glandular tissue**.
- **Fibrous tissue** and **fat** give breasts their size and shape and hold the other structures in place.



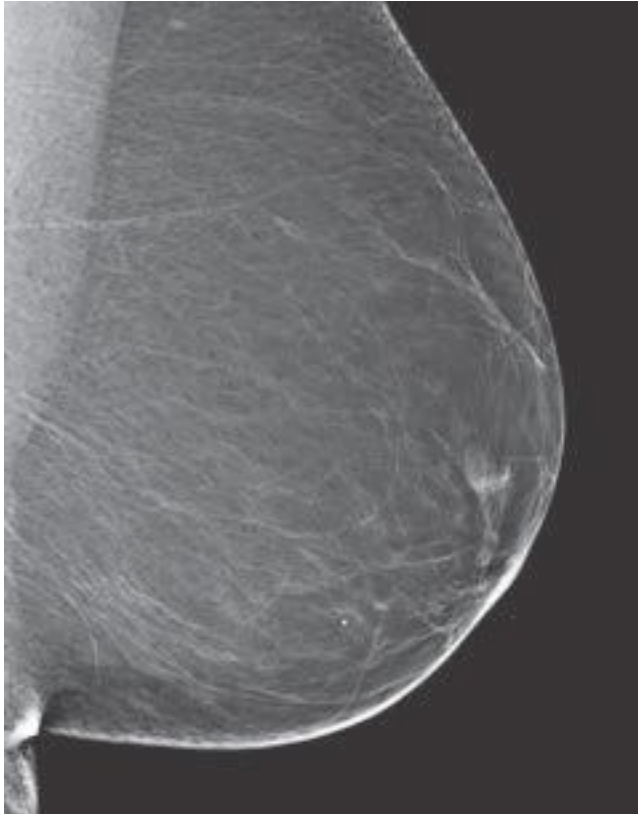
Fibrous and glandular tissue are harder to see through on a mammogram, so your breast tissue may be called 'dense' if you have a lot of these tissues (and not as much fat).

Having dense breast tissue is common. Some women have more dense breast tissue than others. For most women, breasts become less dense with age. But in some women, there's little change.

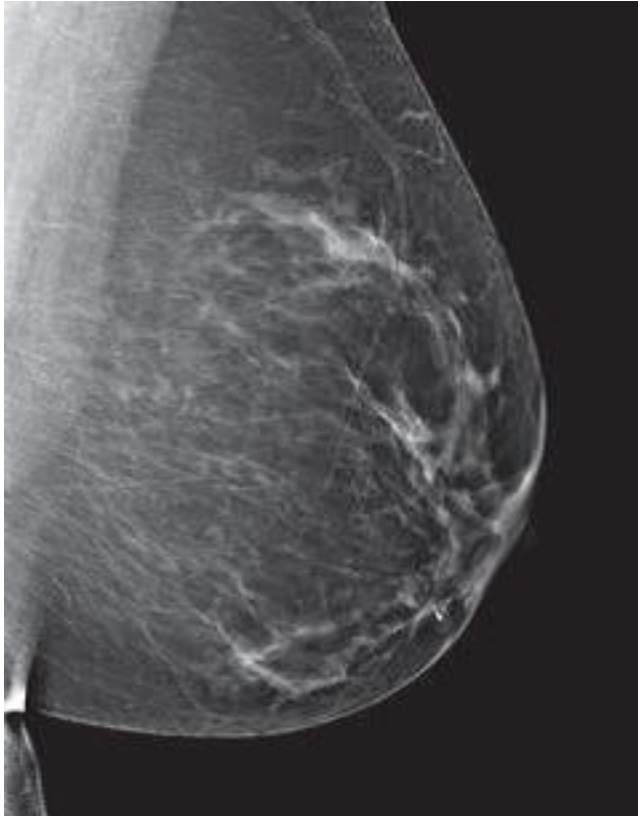
## How do I know if I have dense breasts?

**Radiologists** are doctors who “read” mammograms (and other types of imaging tests). They check your mammogram for **abnormal areas**, and they also look at breast density.

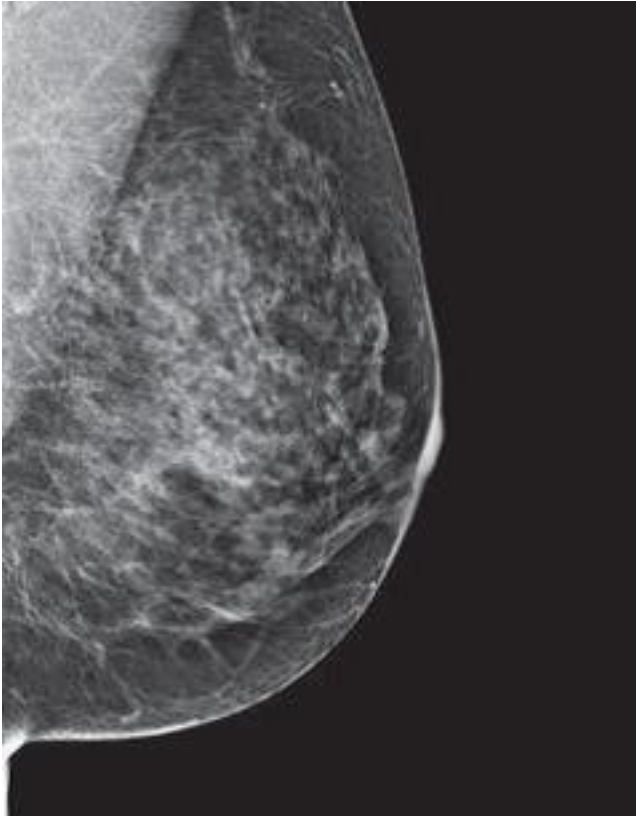
There are 4 categories of breast density. They go from almost all fatty tissue to extremely dense tissue with very little fat. The radiologist looks at your mammograms to determine which of the 4 categories best describes how dense your breasts are:



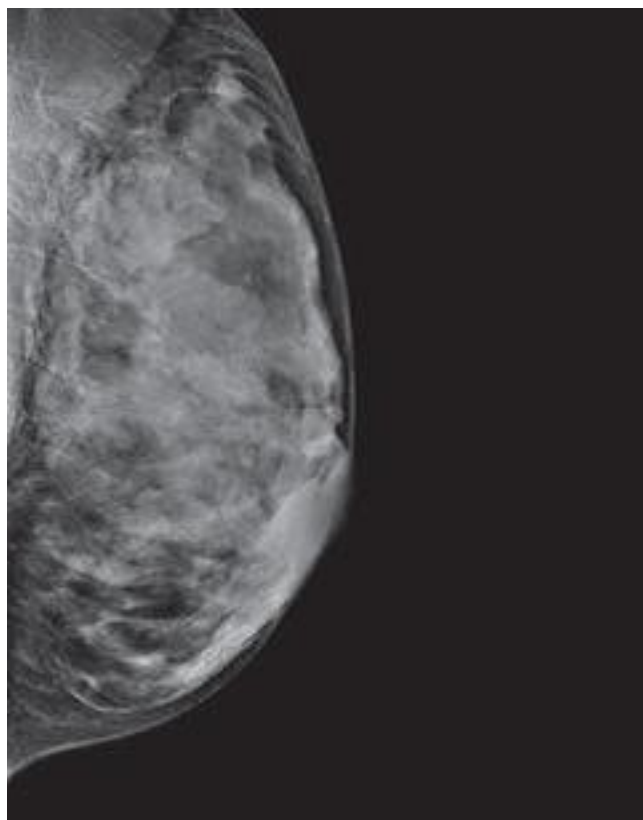
**Category A:** Breasts are almost all fatty tissue.



**Category B:** There are scattered areas of dense glandular and fibrous tissue (seen as white areas on the mammogram).



**Category C:** More of the breast is made of dense glandular and fibrous tissue (described as **heterogeneously dense**). This can make it hard to see small masses in or around the dense tissue, which also appear as white areas.



**Category D:** Breasts are **extremely dense**, which makes it harder to see masses or other findings that may appear as white areas on the mammogram.

In general, patients whose breast density falls into categories C (heterogeneously dense) or D (extremely dense) are considered to have dense breast tissue. This includes about half of all women in the US who have mammograms to look for breast cancer.

[Mammogram reports](#) sent to health care providers typically include a description of breast density, so your health care provider can tell you if your mammogram shows that you have dense breasts. Mammogram reports sent directly to patients often mention breast density as well, although the wording used in these reports is often different (see below).

### **Do mammogram reports have to include breast density?**

At this time, breast density reporting requirements vary by state. But as of September 10, 2024, all mammogram reports sent to patients in the US will be required to include breast density.



## ***State regulations***

In many states, laws require that patients whose mammograms show heterogeneously dense or extremely dense breasts be told that they have dense breasts in the summary of the mammogram report that is sent to patients (sometimes called the *lay summary*).

The specific language required in the report can vary by state.

## ***Federal regulations***

In the US, the Food and Drug Administration (FDA) regulates mammography facilities at the federal level. In March of 2023, the FDA published a rule stating that mammogram reports sent to patients must include breast density, which should be described as either “not dense” or “dense.”

If your breast tissue is **not dense**, the report will say, “Breast tissue can be either dense or not dense. Dense tissue makes it harder to find breast cancer on a mammogram and also raises the risk of developing breast cancer. Your breast tissue is not dense. Talk to your healthcare provider about breast density, risks for breast cancer, and your individual situation.”

If your breast tissue is **dense**, the report will say, “Breast tissue can be either dense or not dense. Dense tissue makes it harder to find breast cancer on a mammogram and also raises the risk of developing breast cancer. Your breast tissue is dense. In some people with dense tissue, other imaging tests in addition to a mammogram may help find cancers. Talk to your healthcare provider about breast density, risks for breast cancer, and your individual situation.”

In addition, mammogram reports sent to healthcare providers must include an overall assessment of breast density using the 4 categories described above.

All mammography centers in the US must comply with this rule by September 10, 2024, although many are already doing so.

## **Why is breast density important?**

Breast density is important for two main reasons:

- **Women who have dense breast tissue have a higher risk of breast cancer** compared to women with less dense breast tissue. It’s unclear at this time why dense breast tissue is linked to breast cancer risk. It may be that dense breast

tissue has more cells that can develop into abnormal cells.

- **Dense breast tissue also makes it harder for radiologists to see cancer on mammograms.** Dense (fibrous and glandular) breast tissue looks white on a mammogram. Breast masses and cancers can also look white, so the dense tissue can make it harder to see them. In contrast, fatty tissue looks almost black on a mammogram, so it's easier to see a tumor that looks white if most of the breast is fat tissue.

## **If I have dense breasts, do I still need a mammogram?**

Yes. Most breast cancers can be seen on a mammogram even in women who have dense breast tissue, so it's still important to get regular mammograms. Mammograms can help save women's lives.

Even if you have a normal mammogram report, you should know how your breasts normally look and feel. Anytime there's a change, you should report it to a health care provider right away.

## **Should I have any other screening tests if I have dense breast tissue?**

At this time, experts do not agree what other tests, if any, should be done in addition to mammograms in women with dense breasts.

[Digital breast tomosynthesis \(3D mammography\)](#) can find some cancers not seen on regular (2D) mammograms. Some studies have suggested 3D mammography might be particularly helpful in women with dense breasts. It can be used as a screening test along with or instead of standard mammography, although it isn't yet available at all imaging centers.

Studies have shown that [breast ultrasound](#) and possibly [magnetic resonance imaging \(MRI\)](#) can also help find some breast cancers that can't be seen on mammograms. But ultrasound and MRI can also show more findings that are not cancer. This can lead to more tests and unnecessary [biopsies](#). And the cost of an ultrasound or MRI may not be covered by insurance.

Talk to your health care provider about whether you should consider any of these tests.

## What should I do if I have dense breast tissue?

If your mammogram report says that you have dense breast tissue, talk with your health care provider about what this means for you. Be sure that your doctor or nurse knows if there's anything in your medical history that increases your risk for breast cancer. To learn more about breast cancer risk factors, see [Breast Cancer Risk and Prevention](#)<sup>1</sup>.

Any woman who's already in a high-risk group (based on inherited gene mutations, a strong family history of breast cancer, or other factors) should have an MRI along with her yearly mammogram. To learn more about if you're in a higher-risk group for breast cancer, see [American Cancer Society Recommendations for the Early Detection of Breast Cancer](#).

### Hyperlinks

1. [www.cancer.org/cancer/types/breast-cancer/risk-and-prevention.html](http://www.cancer.org/cancer/types/breast-cancer/risk-and-prevention.html)

### References

American College of Radiology. BI-RADS ATLAS – Mammography. Reporting System, 2013. Accessed at <https://www.acr.org/-/media/ACR/Files/RADS/BI-RADS/Mammography-Reporting.pdf> on October 1, 2021.

Food and Drug Administration. Mammography Quality Standards Act: Final rule. *Federal Register*. March 10, 2023. 88(47):15126-15171. Accessed at <https://www.govinfo.gov/content/pkg/FR-2023-03-10/pdf/2023-04550.pdf> on March 27, 2023.

Freer PE, Slanetz PJ. Breast density and screening for breast cancer. UpToDate. 2023. Accessed at <https://www.uptodate.com/contents/breast-density-and-screening-for-breast-cancer> on March 28, 2023.

Helvie MA, Patterson SK. Chapter 11: Imaging Analysis: Mammography. In: Harris JR, Lippman ME, Morrow M, Osborne CK, eds. *Diseases of the Breast*. 5th ed. Philadelphia, Pa: Lippincott Williams & Wilkins; 2014.

Kerlikowske K, Ichikawa L, Miglioretti DL, et al. Longitudinal measurement of clinical mammographic breast density to improve estimation of breast cancer risk. *J Natl Cancer Inst*. 2007;99(5):386-395.

Lee CI, Chen LE, Elmore JG. Risk-based breast cancer screening - Implications of breast density. *Medical Clinics of North America*. 2017;101(4):725-741.

Melnikow J, Fenton JJ, Whitlock EP, et al. Supplemental screening for breast cancer in women with dense breasts: A systematic review for the US Preventive Services Task Force. *Ann Intern Med*. 2016;164(4):268-278.

Saslow D, Boetes C, Burke W, et al. American Cancer Society guidelines for breast screening with MRI as an adjunct to mammography. *CA Cancer J Clin*. 2007 Mar-Apr;57(2):75-89.

Venkataraman S, Slanetz PJ, Lee CI. Breast imaging for cancer screening: Mammography and ultrasonography. UpToDate. 2021. Accessed at <https://www.uptodate.com/contents/breast-imaging-for-cancer-screening-mammography-and-ultrasonography> on October 1, 2021.

Last Revised: March 28, 2023

## Limitations of Mammograms

- [False-negative results](#)
- [False-positive results](#)
- [Mammograms might not be helpful for all women](#)
- [Overdiagnosis and overtreatment](#)
- [Radiation exposure](#)

[Mammograms](#) are the best breast cancer screening tests we have at this time. But mammograms have their limits. For example, they aren't 100% accurate in showing if a woman has breast cancer. They can miss some cancers, and sometimes they find things that turn out not to be cancer (but that still need further testing to be sure).

### False-negative results

A **false-negative** mammogram looks normal even though breast cancer is present. Overall, screening mammograms miss about 1 in 8 breast cancers.

- Women with [dense breasts](#) are more likely to get false-negative results.
- False-negative mammograms can give women a false sense of security, thinking that they don't have breast cancer when in fact they do.
- It's important to see your doctor if you have new breast symptoms, even if you've had a normal screening mammogram recently. Additional tests such as a [diagnostic mammogram](#) and/or a [breast ultrasound](#) may be needed to look more closely at the area where you're having symptoms.

## False-positive results

A **false-positive** mammogram looks abnormal even though there is no cancer in the breast. Abnormal mammograms often require extra testing ([diagnostic mammograms](#), [ultrasound](#), and sometimes [MRI](#) or even a [breast biopsy](#)) to find out if the change is cancer.

- False-positive results are more common in women who are younger, have dense breasts, have had breast biopsies, have breast cancer in the family, or are taking estrogen.
- About half of the women getting annual mammograms over a 10-year period will have a false-positive finding at some point.
- The odds of a false-positive finding are higher for the first mammogram (or if previous mammograms aren't available for comparison). Women who have past mammograms available for comparison reduce their odds of a false-positive finding by about half.
- False-positive mammograms can cause anxiety. They can also lead to [extra tests](#) to be sure cancer isn't there, which cost time and money and maybe even physical discomfort.

## Mammograms might not be helpful for all women

The value of a screening mammogram depends on a woman's overall health. Finding breast cancer early may not help her live longer if she has other serious or life-threatening health problems, such as serious heart, kidney, liver, or lung disease. The [American Cancer Society breast cancer screening guidelines](#) emphasize that women with serious health problems or short life expectancies should discuss with their doctors whether they should continue having mammograms. Our guidelines also stress that age

alone should not be the reason to stop having regular mammograms.

It's important to know that even though mammograms can often find breast cancers that are too small to be felt, treating a small tumor does not always mean it can be cured. A fast-growing or aggressive cancer might have already spread, even if the tumor in the breast is still small.

## Overdiagnosis and overtreatment

Screening mammograms can often find invasive breast cancer and [ductal carcinoma in situ](#)<sup>1</sup> (DCIS, cancer cells in the lining of breast ducts) that need to be treated. But it's possible that some of the invasive cancers and DCIS found on mammograms would never grow or spread. (Finding cancers that would never cause problems is called **overdiagnosis**.) These cancers are not life-threatening, and never would have been found or treated if the woman had not gotten a mammogram. The problem is that doctors can't tell these cancers from those that will grow and spread.

Overdiagnosis leads to some women getting treatment that's not really needed (**overtreatment**), because the cancer never would have caused any problems. Doctors can't always tell which cancers could be life-threatening and which would never cause problems. Because of this, they advise treating all breast cancers. This exposes some women to the side effects of cancer treatment, even though it wasn't really needed.

Still, overdiagnosis isn't thought to happen very often. There's a wide range of estimates of the percentage of breast cancers that might be overdiagnosed by mammography, but the most credible estimates range from 1% to 10%.

## Radiation exposure

Because mammograms are x-ray tests, they expose the breasts to radiation. The amount of radiation from each mammogram is low, but it can still add up over time. For more on this, see [Mammogram Basics](#).

## Hyperlinks

1. [www.cancer.org/cancer/types/breast-cancer/about/types-of-breast-cancer/dcis.html](http://www.cancer.org/cancer/types/breast-cancer/about/types-of-breast-cancer/dcis.html)

## References

Elmore JG, Barton MB, Mocerri VM, Polk S, Arena PJ, Fletcher SW. Ten-year risk of false positive screening mammograms and clinical breast examinations. *N Engl J Med*. 1998;338(16):1089.

Elmore JG, Lee CI. Screening for breast cancer: Evidence for effectiveness and harms. UpToDate. 2021. Accessed at <https://www.uptodate.com/contents/screening-for-breast-cancer-evidence-for-effectiveness-and-harms> on October 1, 2021.

Hubbard RA, Kerlikowske K, Flowers CI, et al. Cumulative probability of false-positive recall or biopsy recommendation after 10 years of screening mammography: A cohort study. *Ann Intern Med* 2011;155:481-492.

Lauby-Secretan B, Scoccianti C, Loomis D, et al. Breast-cancer screening--viewpoint of the IARC Working Group. *N Engl J Med*. 2015;372(24):2353-2358.

Lee CI, Elmore JG. Chapter 10: Breast Cancer Screening. In: Harris JR, Lippman ME, Morrow M, Osborne CK, eds. *Diseases of the Breast*. 5th ed. Philadelphia, Pa: Lippincott Williams & Wilkins; 2014.

Puliti D, Duffey SW, Miccinesi G, et al. Overdiagnosis in mammographic screening for breast cancer in Europe: A literature review. *J Med Screen*, 2012;19:Suppl 1:42-56.

Rosenberg RD, Hunt WC, Williamson MR, et al. Effects of age, breast density, ethnicity, and estrogen replacement therapy on screening mammographic sensitivity and cancer stage at diagnosis: Review of 183,134 screening mammograms in Albuquerque, New Mexico. *Radiology* 1998; 209:511–518.

Venkataraman S, Slanetz PJ, Lee CI. Breast imaging for cancer screening: Mammography and ultrasonography. UpToDate. 2021. Accessed at <https://www.uptodate.com/contents/breast-imaging-for-cancer-screening-mammography-and-ultrasonography> on October 1, 2021.

Last Revised: January 14, 2022

---

# Mammograms After Breast Cancer

# Surgery

- [Mammograms after breast-conserving surgery](#)
- [Mammograms after mastectomy](#)

Nearly all women with breast cancer will have surgery at some point as part of their treatment. There are many different kinds of [breast cancer surgery](#)<sup>1</sup>. The type of surgery you have had will affect if you need to get mammograms in the future:

- If you have had **breast-conserving surgery (BCS)**, you will still need to get mammograms of the treated breast.
- If you have had a **mastectomy**, you most likely won't need a mammogram of that breast.

However, if you had surgery (of any type) on only one breast, you will still need to get mammograms of the other breast. This is very important, because women who have had breast cancer have a higher risk of developing a new cancer in the other breast.

While **the American Cancer Society does not have specific guidelines for mammograms or other breast imaging in women who have been treated for breast cancer**, there is information available about what these women will probably need to do.

## Mammograms after breast-conserving surgery

Most experts recommend that women who have had [breast-conserving surgery](#)<sup>2</sup> (BCS, sometimes called a partial mastectomy or lumpectomy) get a mammogram of the treated breast 6 to 12 months after radiation treatment ends. Surgery and radiation both cause changes in the skin and breast tissues that will show up on the mammogram, which might make it harder to read.

The mammogram done at this time serves as a new baseline for the affected breast. Future mammograms will be compared with this one, to help the doctor check on healing and look for signs that the cancer might have come back (recurred).

Follow-up mammograms of the treated breast are typically done at least yearly after that, but some doctors may recommend that you have mammograms more often. You will still need to have routine mammograms on the other (untreated) breast as well.



## Mammograms after mastectomy

Women who have had a [mastectomy](#)<sup>3</sup> (including simple mastectomy, modified radical mastectomy, and radical mastectomy) to treat breast cancer should not need further routine screening mammograms on that side, but will still need regular mammograms on the remaining breast. If both breasts have been removed (a double or bilateral mastectomy), mammograms should no longer be needed because there shouldn't be enough breast tissue left to do a mammogram. Cancer might come back in the skin or chest wall on that side, but if this happens it is usually found by feeling it (either during a physical exam or a breast self-exam).

It's possible for women with **reconstructed breasts** to get mammograms, but experts agree that women who have [breast reconstruction](#)<sup>4</sup> after a simple, modified radical, or radical mastectomy don't need routine mammograms of the affected breast(s). Still, if an area of concern is found during a physical exam on a woman who has had breast reconstruction, a [diagnostic mammogram](#) and [breast ultrasound](#) may be done. [Breast MRI](#) may also sometimes be used to look at the area closely if the mammogram and ultrasound results aren't clear.

For women who have had a **nipple-sparing mastectomy**, also called a **subcutaneous mastectomy**, some doctors might recommend follow-up mammograms because some breast tissue can be left behind under the nipple.

**If you're not sure what type of mastectomy you had or if you need to get mammograms, be sure to ask your doctor.**

## Hyperlinks

1. [www.cancer.org/cancer/types/breast-cancer/treatment/surgery-for-breast-cancer.html](http://www.cancer.org/cancer/types/breast-cancer/treatment/surgery-for-breast-cancer.html)
2. [www.cancer.org/cancer/types/breast-cancer/treatment/surgery-for-breast-cancer/breast-conserving-surgery-lumpectomy.html](http://www.cancer.org/cancer/types/breast-cancer/treatment/surgery-for-breast-cancer/breast-conserving-surgery-lumpectomy.html)
3. [www.cancer.org/cancer/types/breast-cancer/treatment/surgery-for-breast-cancer/mastectomy.html](http://www.cancer.org/cancer/types/breast-cancer/treatment/surgery-for-breast-cancer/mastectomy.html)
4. [www.cancer.org/cancer/types/breast-cancer/reconstruction-surgery.html](http://www.cancer.org/cancer/types/breast-cancer/reconstruction-surgery.html)

## References

Khatcheressian JL, Hurley P, Bantug E, Breast cancer follow-up and management after

primary treatment: American Society of Clinical Oncology clinical practice guideline update. *J Clin Oncol*. 2013;31(7):961-965.

Nahabedian M. Overview of breast reconstruction. UpToDate. 2021. Accessed at <https://www.uptodate.com/contents/overview-of-breast-reconstruction> on October 4, 2021.

National Comprehensive Cancer Network. NCCN Clinical Practice Guidelines in Oncology. Breast Cancer. Version 2.2021. Accessed at [www.nccn.org/professionals/physician\\_gls/pdf/breast.pdf](http://www.nccn.org/professionals/physician_gls/pdf/breast.pdf) on October 4, 2021.

Ruddy KJ, Partridge AH. Approach to the patient following treatment for breast cancer. UpToDate. 2021. Accessed at <https://www.uptodate.com/contents/approach-to-the-patient-following-treatment-for-breast-cancer> on October 4, 2021.

Venkataraman S, Slanetz PJ. Breast imaging for cancer screening: Mammography and ultrasonography. UpToDate. 2021. Accessed at <https://www.uptodate.com/contents/breast-imaging-for-cancer-screening-mammography-and-ultrasonography> on October 4, 2021.

Last Revised: January 14, 2022

---

## Mammograms for Women with Breast Implants

If you have breast implants, you should still get regular screening mammograms [as recommended](#) (unless you had both breasts removed with a [bilateral mastectomy](#) before getting the implants).

It's important to tell the technologist you have implants before your mammogram is started. In fact, it's best to mention this when you make the appointment to have your mammogram done. This way you can find out if the facility has experience doing mammograms in women with breast implants.

You should be aware that both silicone and saline implants can make it hard for the doctor to see the breast tissue that is in line with them on the mammogram.

To help the doctor see as much breast tissue as possible, women with implants have 4 extra pictures done (2 on each breast), as well as the 4 standard pictures taken during a [screening mammogram](#). In these extra pictures, called **implant displacement (ID) views**, the implant is pushed back against the chest wall and the breast is pulled forward over it and then compressed. This allows better imaging of the front part of each breast so the doctor can get a better look at the breast tissue.

Implant displacement views are harder to do and can be uncomfortable if areas of scar tissue (called *contractures*) have formed around the implants. ID views are easier if the implants were placed underneath (behind) the chest muscles.

Very rarely, the mammogram process can rupture an implant. This is another important reason to make sure the mammography facility knows you have implants.

## References

Elmore JG, Lee CI. Screening for breast cancer: Strategies and recommendations. UpToDate. 2021. Accessed at <https://www.uptodate.com/contents/screening-for-breast-cancer-strategies-and-recommendations> on October 4, 2021.

Helvie MA, Patterson SK. Chapter 11: Imaging Analysis: Mammography. In: Harris JR, Lippman ME, Morrow M, Osborne CK, eds. *Diseases of the Breast*. 5th ed. Philadelphia, Pa: Lippincott Williams & Wilkins; 2014.

Nahabedian M. Implant-based breast reconstruction and augmentation. UpToDate. 2021. Accessed at <https://www.uptodate.com/contents/implant-based-breast-reconstruction-and-augmentation> on October 4, 2021.

Last Revised: January 14, 2022

---

# Breast Ultrasound

- [When is breast ultrasound used?](#)
- [How is a breast ultrasound done?](#)
- [How are breast ultrasound results reported?](#)

Breast ultrasound uses sound waves and their echoes to make computer pictures of the

inside of the breast. It can show certain breast changes, like fluid-filled cysts, that can be harder to see on mammograms.

## When is breast ultrasound used?

Ultrasound is not typically used as a routine screening test for breast cancer. But it can be useful for looking at some breast changes, such as lumps (especially those that can be felt but not seen on a mammogram). Ultrasound can be especially helpful in women with [dense breast tissue](#), which can make it hard to see abnormal areas on mammograms. It also can be used to get a better look at a suspicious area that was seen on a mammogram.

Ultrasound is useful because it can often tell the difference between fluid-filled masses like [cysts](#)<sup>1</sup> (which are very unlikely to be cancer) and solid masses (which might need further testing to be sure they're not cancer).

Ultrasound can also be used to help guide a [biopsy](#) needle into an area of the breast so that cells can be taken out and tested for cancer. This can also be done in swollen lymph nodes under the arm.

Ultrasound is widely available and is fairly easy to have done, and it does not expose a person to radiation. It also tends to cost less than other testing options.

## How is a breast ultrasound done?

Most often, ultrasound is done using a handheld, wand-like instrument called *atransducer*. First a gel is put on the skin and/or the transducer, and then the transducer is moved around over the skin. It sends out sound waves and picks up the echoes as they bounce off body tissues deeper under the skin. These echoes are made into a picture on a computer screen. You might feel some pressure as the transducer is moved around on your skin, but it should not be painful.

**Automated breast ultrasound (ABUS)** is an option at some imaging centers. This technique uses a much larger transducer to take hundreds of images that cover nearly the entire breast. ABUS might sometimes be done as an added screening exam for women who have dense breasts. It might also be used in women who have abnormal findings on other imaging tests or who have breast symptoms. When ABUS is done, a second handheld ultrasound is often needed to get more pictures of any suspicious areas.

## How are breast ultrasound results reported?

Doctors use the same standard system to describe results of mammograms, breast ultrasound, and breast MRI. This system (called the **Breast Imaging Reporting and Data System** or **BI-RADS**) sorts the results into categories numbered 0 through 6.

By sorting the results into these categories, doctors can describe what they find on an ultrasound using the same words and terms. This makes communicating about these test results and following up after the tests much easier.

For more details on the BI-RADS categories, see [Understanding Your Mammogram Report](#). While the categories are the same for each of these imaging tests, the recommended next steps after these tests might be different.

## Hyperlinks

1. [www.cancer.org/cancer/types/breast-cancer/non-cancerous-breast-conditions/fibrosis-and-simple-cysts-in-the-breast.html](http://www.cancer.org/cancer/types/breast-cancer/non-cancerous-breast-conditions/fibrosis-and-simple-cysts-in-the-breast.html)

## References

American College of Radiology. ACR BI-RADS ATLAS – Breast Ultrasound. Reporting System. 2013. Accessed at <https://www.acr.org/-/media/ACR/Files/RADS/BI-RADS/US-Reporting.pdf> on November 29, 2021.

Esserman LJ, Joe BN. Diagnostic evaluation of women with suspected breast cancer. UpToDate. 2021. Accessed at <https://www.uptodate.com/contents/diagnostic-evaluation-of-women-with-suspected-breast-cancer> on October 11, 2021.

National Comprehensive Cancer Network. NCCN Clinical Practice Guidelines in Oncology. Breast Cancer Screening and Diagnosis. Version 1.2021. Accessed at [https://www.nccn.org/professionals/physician\\_gls/pdf/breast-screening.pdf](https://www.nccn.org/professionals/physician_gls/pdf/breast-screening.pdf) on October 11, 2021.

Rella R, Belli P, Giuliani M, et al. Automated breast ultrasonography (ABUS) in the screening and diagnostic setting: Indications and practical use. *Acad Radiol*. 2018;25(11):1457-1470.

Sedgwick EL. Chapter 12: Imaging Analysis: Ultrasonography. In: Harris JR, Lippman

ME, Morrow M, Osborne CK, eds. *Diseases of the Breast*. 5th ed. Philadelphia, Pa: Lippincott Williams & Wilkins; 2014.

Venkataraman S, Slanetz PJ, Lee CI. Breast imaging for cancer screening: Mammography and ultrasonography. UpToDate. 2021. Accessed at <https://www.uptodate.com/contents/breast-imaging-for-cancer-screening-mammography-and-ultrasonography> on October 11, 2021.

Last Revised: January 14, 2022

## Breast MRI

- [When is breast MRI used?](#)
- [What you need to know about getting a breast MRI](#)
- [Tips for getting ready for the test](#)
- [What's it like to get a breast MRI?](#)
- [How are breast MRI results reported?](#)

Breast MRI (magnetic resonance imaging) uses radio waves and strong magnets to make detailed pictures of the inside of the breast.

### When is breast MRI used?

Breast MRI might be used in different situations.

**To screen for breast cancer:** For certain women at high risk for breast cancer, [a screening breast MRI is recommended along with a yearly mammogram](#). MRI is not recommended as a screening test by itself, because it can miss some cancers that a mammogram would find.

Although MRI can find some cancers not seen on a mammogram, it's also more likely to find things that turn out not to be cancer (called a *false positive*). This can result in some women getting tests and/or [biopsies](#) that end up not being needed. This is why MRI is not recommended as a screening test for women at average risk of breast cancer.

**To look at the breasts if someone has symptoms that might be from breast**

**cancer:** Breast MRI might sometimes be done if breast cancer is suspected (based on [symptoms](#) or exam findings, such as suspicious nipple discharge). Other imaging tests such as [mammograms](#) and [breast ultrasound](#) are usually done first, but MRI might be done if the results of these tests aren't clear.

**To help determine the extent of breast cancer:** If breast cancer has already been diagnosed, breast MRI is sometimes done to help determine the exact size and location of the cancer, to look for other tumors in the breast, and to check for tumors in the other breast. Breast MRI isn't always helpful in this setting, so not every woman who has been diagnosed with breast cancer needs this test.

**To check for silicone breast implant leaks:** In women with [silicone breast implants](#)<sup>1</sup>, breast MRI can be used to check for implant leaks. This isn't used for women with saline breast implants.

## What you need to know about getting a breast MRI

Just as mammograms are done using x-ray machines specially designed for the breasts, breast MRI also requires special equipment. This MRI machine has a special device called a *dedicated breast coil* to image the breasts. Not all hospitals and imaging centers have dedicated breast MRI equipment. If you are having a breast MRI, it's important to have it at a facility that has dedicated equipment and can do an MRI-guided breast biopsy if needed, or a facility that partners with one that can.

MRI uses strong magnets instead of radiation to make very detailed, cross-sectional pictures of the body. An MRI scanner takes pictures from many angles, as if someone were looking at a slice of your body from the front, from the side, or from above your head. MRI creates pictures of soft tissue parts of the body that would sometimes be hard to see using other imaging tests.

Unlike mammograms or breast ultrasound, breast MRI requires that you have a contrast dye injected into your vein (through an IV line) before the pictures are taken. This helps make any abnormal areas in your breasts easier to see.

## Tips for getting ready for the test

**Check with your insurance provider before getting an MRI:** Breast MRI can cost a lot, and it may need to be approved by your insurance company before the scan is done. Most private insurance plans that pay for mammogram screening also pay for MRI as a screening test if a woman is shown to be at high risk. It might help to go to a center with a breast health or high-risk clinic, where the staff has experience getting

approval for breast MRIs.

**Follow all instructions:** You don't usually need a special diet or preparation before an MRI, but follow any instructions you're given.

**If you have trouble with enclosed spaces:** Breast MRI is most often done while you are lying on your belly with your arms above your head inside a long, narrow tube. If being in a tight space might be a problem for you, you might need to take medicine to help you relax while in the scanner. Talking with the technologist or a patient counselor or getting a tour of the MRI machine before the test can also help. You'll be in the exam room alone during the test, but you can talk to the MR technologist, who can see and hear what's going on.

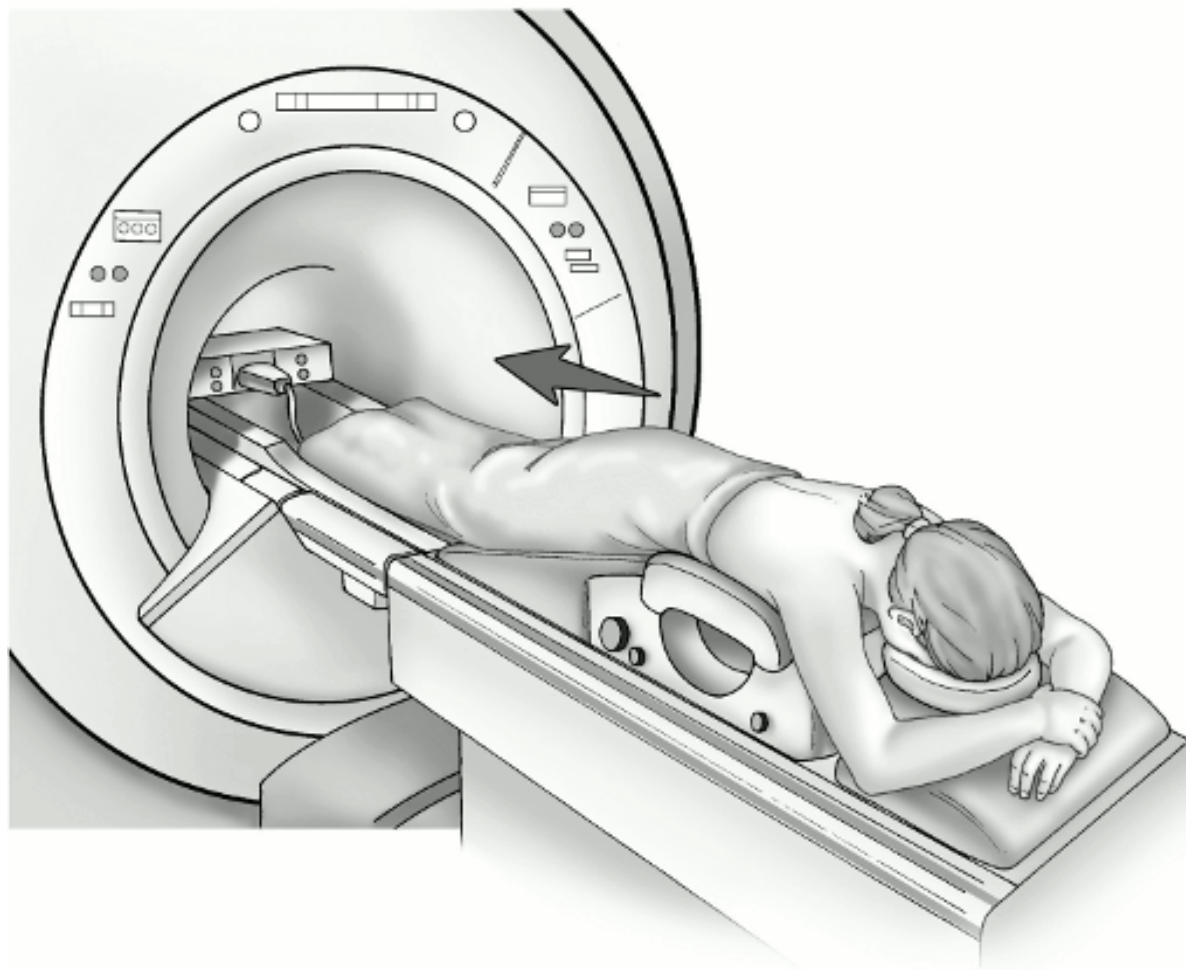
**Remove metal objects:** Before the test, you'll be asked to undress and put on a gown or other clothes without zippers or metal. Be sure to remove any metal objects you can, like hair clips, jewelry, dental work, and body piercings.

**If you have metal in your body:** Before the scan, the technologist will ask you if you have any metal in your body. Some metallic objects will not cause problems, but others can.

Let your technologist know if you have any medical implants or clips in your body. If you have any of these types of medical implants, you should not even enter the MRI scanning area unless you're told it's OK to do so by a radiologist or technologist:

- An implanted defibrillator or pacemaker
- Clips used on a brain aneurysm
- A cochlear (ear) implant
- Metal coils inside blood vessels





© Sam and Amy Collins

## Breast MRI

### What's it like to get a breast MRI?

MRI scans are usually done in an outpatient setting in a hospital or clinic. You'll first have an IV line placed in a vein in your arm so that contrast material can be injected during the test.

You'll lie face down on a narrow, flat table with your arms above your head. Your breasts will hang down into an opening in the table so they can be scanned without being compressed. The technologist may use pillows to make you comfortable and help keep you from moving. The table then slides into a long, narrow tube.

The test is painless, but you have to lie still inside the narrow tube. You may be asked to hold your breath or keep very still during certain parts of the test. The machine may make loud thumping, clicking, and whirring noises, much like the sound of a washing

machine, as the magnet switches on and off. Some facilities give you earplugs or headphones to help block noise out during testing.

When breast MRI is done to look for breast cancer, a contrast material called *gadolinium* is injected into a vein in the arm during the exam, which helps show any abnormal areas of breast tissue. (This is different from the contrast dye used in CT scans.) Let the technologist know if you have any allergies or have had problems before with any contrast or dye used in imaging tests.

It's important to stay very still while the test is being done, which helps ensure the images will be of good quality.

Each set of images usually takes a few minutes, and the whole test usually takes about 30 to 45 minutes. After the test, you may be asked to wait while the pictures are checked to see if more are needed.

For a newer MRI technique, known as [abbreviated breast MRI](#), fewer images are taken, so the scan takes less time (usually about 10 minutes).

## How are breast MRI results reported?

Doctors use the same standard system to describe results of mammograms, breast ultrasound, and breast MRI. This system (called the **Breast Imaging Reporting and Data System** or **BI-RADS**) sorts the results into categories numbered 0 through 6.

By sorting the results into these categories, doctors can describe what they find on a breast MRI using the same words and terms. This makes communicating about these test results and following up after the tests much easier.

For more details on the BI-RADS categories, see [Understanding Your Mammogram Report](#). While the categories are the same for each of these types of imaging tests, the recommended next steps after these tests might be different.

## Hyperlinks

1. [www.cancer.org/cancer/types/breast-cancer/reconstruction-surgery/breast-reconstruction-options/breast-reconstruction-using-implants.html](http://www.cancer.org/cancer/types/breast-cancer/reconstruction-surgery/breast-reconstruction-options/breast-reconstruction-using-implants.html)

## References

American College of Radiology. ACR BI-RADS ATLAS – Breast MRI. Reporting System. 2013. Accessed at <https://www.acr.org/-/media/ACR/Files/RADS/BI-RADS/MRI-Reporting.pdf> on November 29, 2021.

Esserman LJ, Joe BN. Diagnostic evaluation of suspected breast cancer. UpToDate. 2021. Accessed at <https://www.uptodate.com/contents/diagnostic-evaluation-of-suspected-breast-cancer> on October 11, 2021.

Gupta D, Mendelson EB, Karst I. Nipple discharge: Current clinical and imaging evaluation. *Am J Roentgenol*. 2021;216(2):330-339.

National Comprehensive Cancer Network. NCCN Clinical Practice Guidelines in Oncology. Breast Cancer. Version 8.2021. Accessed at [https://www.nccn.org/professionals/physician\\_gls/pdf/breast.pdf](https://www.nccn.org/professionals/physician_gls/pdf/breast.pdf) on October 11, 2021.

Slanetz PJ. MRI of the breast and emerging technologies. UpToDate. 2021. Accessed at <https://www.uptodate.com/contents/mri-of-the-breast-and-emerging-technologies> on October 11, 2021.

Weinstein SP, Roth SO. Chapter 12: Imaging Analysis: Magnetic Resonance Imaging. In: Harris JR, Lippman ME, Morrow M, Osborne CK, eds. *Diseases of the Breast*. 5th ed. Philadelphia, Pa: Lippincott Williams & Wilkins; 2014.

Last Revised: January 14, 2022

## Newer and Experimental Breast Imaging Tests

- [Abbreviated breast MRI \(fast breast MRI\)](#)
- [Nuclear medicine tests \(radionuclide imaging\)](#)
- [Contrast-enhanced mammography \(CEM\)](#)
- [Elastography](#)
- [Optical imaging tests](#)
- [Electrical impedance tomography \(EIT\)](#)

The most commonly used breast imaging tests at this time are [mammograms](#),

[ultrasound](#), and [breast MRI](#). Other tests, such as CT scans, bone scans, or PET scans might sometimes be done [to help find out if breast cancer has spread](#)<sup>1</sup>.

Newer types of tests are now being developed for breast imaging. Some of these, such as [breast tomosynthesis \(3D mammography\)](#), are already being used in some centers. Other tests are still being studied, and it will take time to see if they are as good as or better than those used today.

### **Abbreviated breast MRI (fast breast MRI)**

This is a newer technique that is done with a standard breast MRI scanner. But fewer images are taken (over a shorter period of time) than with a standard breast MRI. As with standard breast MRI, a contrast material called *gadolinium* is given through an IV line before some of the images are taken. Abbreviated breast MRI is now being studied as a possible screening test for breast cancer, especially in women with dense breasts, to see if it provides the same information as a standard breast MRI.

### **Nuclear medicine tests (radionuclide imaging)**

For these tests, a small amount of radioactive material (known as a *tracer*) is injected into the blood. The tracer is more likely to collect in cancer cells. A special camera can then be used to see the tracer in the breast (or other parts of the body).

For **molecular breast imaging (MBI)**, also known as **scintimammography** or **breast-specific gamma imaging (BSGI)**, a tracer called *technetium-99m sestamibi* is injected into the blood, and a special camera is then used to see the tracer while the breast is gently compressed. This test is being studied mainly as a way to follow up breast problems (such as a lump or an abnormal mammogram), or to help determine the extent of breast cancer that has already been diagnosed. It's also being studied as a screening test for use along with mammograms to look for cancer in women with [dense breasts](#). One potential drawback is that it exposes the whole body to radiation, so it's unlikely this test would be used for screening every year.

For a **positron emission tomography (PET) scan**, a different type of radioactive tracer is injected into the blood. Standard PET scans, which use a form of radioactive sugar (known as *FDG*), are sometimes done if there's a concern that breast cancer might have spread to other parts of the body. A newer type of tracer, known as **fluoroestradiol F-18**, is now available to look for the spread of some advanced estrogen receptor (ER)-positive breast cancers.

**Positron emission mammography (PEM)** is a newer imaging test of the breast that

combines some aspects of a PET scan and a mammogram. PEM uses the same type of radioactive tracer injected into the blood as a PET scan. The breast is then lightly compressed while the images are taken, as with a mammogram. PEM may be better able to detect small clusters of cancer cells within the breast than standard mammography. This is because it takes into account how active the breast cells are, as opposed to just their structure. PEM is being studied mainly in women with breast cancer to see if it can help determine the extent of the cancer. PEM exposes the whole body to radiation, so it isn't likely to be used every year for breast cancer screening.

## **Contrast-enhanced mammography (CEM)**

Also known as **contrast-enhanced spectral mammography (CESM)**, this is a newer test in which a contrast dye containing iodine is injected into the blood a few minutes before two sets of mammograms (using different energy levels) are taken. The contrast can help the x-rays show any abnormal areas in the breasts. This test can be used to get a better look at areas that appear abnormal on a standard mammogram, or to help assess the extent of a tumor in women just diagnosed with breast cancer. Studies are now comparing it to breast MRI in these settings (where it might be particularly useful if MRI can't be done for some reason), as well as possibly for use in screening women with dense breasts. If it proves to be as good as MRI, CEM could become more widely used because it is quicker to do and is less expensive than MRI.

## **Elastography**

This is a test that can be done as part of an ultrasound exam. It's based on the idea that breast cancer tumors tend to be firmer and stiffer than the surrounding breast tissue. For this technique, the breast is compressed slightly, and the ultrasound can show how firm a suspicious area is. This test might prove to be useful in telling if the area is more likely to be cancer or a benign (non-cancerous) tumor.

## **Optical imaging tests**

These tests pass light into the breast and then measure the light that returns or passes through the tissue. The technique does not use radiation and does not require breast compression. Early studies going on now are looking at combining optical imaging with other tests like MRI, ultrasound, or 3D mammography to help look for breast cancer.

## **Electrical impedance tomography (EIT)**

EIT is based on the idea that breast cancer cells conduct electricity differently from

normal cells. For this test, small electrodes are taped to the skin to pass very small electrical currents through the breast and then detect them on the skin. EIT does not use radiation or compress the breasts. This test might prove to be useful in helping to classify tumors found on mammograms. But so far there hasn't been enough clinical testing to show if it's useful for breast cancer screening.

## Hyperlinks

1. [www.cancer.org/cancer/types/breast-cancer/understanding-a-breast-cancer-diagnosis/tests-to-find-out-if-breast-cancer-has-spread.html](http://www.cancer.org/cancer/types/breast-cancer/understanding-a-breast-cancer-diagnosis/tests-to-find-out-if-breast-cancer-has-spread.html)

## References

Bruening W, Uhl S, Fontanarosa J, et al. Noninvasive Diagnostic Tests for Breast Abnormalities: Update of a 2006 Review [Internet]. Rockville (MD): Agency for Healthcare Research and Quality (US); 2012 Feb. Accessed at [www.ncbi.nlm.nih.gov/books/NBK84530/](http://www.ncbi.nlm.nih.gov/books/NBK84530/) on October 13, 2021.

Caldarella C, Treglia G, Giordano A. Diagnostic performance of dedicated positron emission mammography using fluorine-18-fluorodeoxyglucose in women with suspicious breast lesions: A meta-analysis. *Clin Breast Cancer*. 2014;14(4):241-248.

Comstock CE, Gatsonis C, Newstead GM, et al. Comparison of abbreviated breast MRI vs digital breast tomosynthesis for breast cancer detection among women with dense breasts undergoing screening. *JAMA*. 2020;323(8):746-756.

Jochelson MS. Chapter 12: Imaging Analysis: New Breast Imaging Techniques. In: Harris JR, Lippman ME, Morrow M, Osborne CK, eds. *Diseases of the Breast*. 5th ed. Philadelphia, Pa: Lippincott Williams & Wilkins; 2014.

Lee CI, Elmore JG. Chapter 10: Breast Cancer Screening. In: Harris JR, Lippman ME, Morrow M, Osborne CK, eds. *Diseases of the Breast*. 5th ed. Philadelphia, Pa: Lippincott Williams & Wilkins; 2014.

National Comprehensive Cancer Network. NCCN Clinical Practice Guidelines in Oncology. Breast Cancer. Version 8.2021. Accessed at [https://www.nccn.org/professionals/physician\\_gls/pdf/breast.pdf](https://www.nccn.org/professionals/physician_gls/pdf/breast.pdf) on October 13, 2021.

Perry H, Phillips J, Dialani V, et al. Contrast-enhanced mammography: A systematic

guide to interpretation and reporting. *AJR Am J Roentgenol.* 2019;212(1):222-231.

Rhodes DJ, Hruska CB, Phillips SW, Whaley DH, O'Connor MK. Dedicated dual-head gamma imaging for breast cancer screening in women with mammographically dense breasts. *Radiology.* 2011;258(1):106-118.

Slanetz PJ. MRI of the breast and emerging technologies. UpToDate. 2021. Accessed at <https://www.uptodate.com/contents/mri-of-the-breast-and-emerging-technologies> on October 13, 2021.

Weigert JM, Bertrand ML, Lanzkowsky L, Stern LH, Kieper DA. Results of a multicenter patient registry to determine the clinical impact of breast-specific gamma imaging, a molecular breast imaging technique. *AJR Am J Roentgenol.* 2012;198(1):W69-75.

Last Revised: January 14, 2022

## Breast Cancer Signs and Symptoms

Knowing how your breasts normally look and feel is an important part of your breast health. Although [having regular screening tests](#) for breast cancer is important, [mammograms](#) do not find every breast cancer. This means it's also important for you to know what your breasts normally look and feel like, so you'll be aware of any changes in your breasts.

The most common symptom of breast cancer is **a new lump or mass** (although most breast lumps are *not* cancer). A painless, hard mass that has irregular edges is more likely to be cancer, but breast cancers can be also soft, round, tender, or even painful.

Other possible symptoms of breast cancer include:

- **Swelling of all or part of a breast** (even if no lump is felt)
- **Skin dimpling** (sometimes looking like an orange peel)
- **Breast or nipple pain**
- **Nipple retraction** (turning inward)
- **Nipple or breast skin that is red, dry, flaking, or thickened**
- **Nipple discharge** (other than breast milk)
- **Swollen lymph nodes under the arm or near the collar bone** (Sometimes this

can be a sign of breast cancer spread even before the original tumor in the breast is large enough to be felt.)

Many of these symptoms can also be caused by [benign \(non-cancerous\) breast conditions](#)<sup>1</sup>. Still, **it's important to have any new breast mass, lump, or other change checked by an experienced health care professional** so the cause can be found and treated, if needed.

Remember that knowing what to look for does not take the place of having regular screening for breast cancer. Screening mammography can often help find breast cancer early, before any symptoms appear. Finding breast cancer early gives you a better chance of successful treatment.

## Hyperlinks

1. [www.cancer.org/cancer/types/breast-cancer/non-cancerous-breast-conditions.html](http://www.cancer.org/cancer/types/breast-cancer/non-cancerous-breast-conditions.html)

## References

Henry NL, Shah PD, Haider I, et al. Chapter 88: Cancer of the Breast. In: Niederhuber JE, Armitage JO, Doroshow JH, Kastan MB, Tepper JE, eds. *Abeloff's Clinical Oncology*. 6th ed. Philadelphia, Pa: Elsevier; 2020.

Morrow M. Chapter 3: Physical Exam of the Breast. In: Harris JR, Lippman ME, Morrow M, Osborne CK, eds. *Diseases of the Breast*. 5th ed. Philadelphia: Wolters Kluwer Health; 2014.

National Cancer Institute. Physician Data Query (PDQ). Breast Cancer Treatment (Adult) – Patient Version. 2021. Accessed at <https://www.cancer.gov/types/breast/patient/breast-treatment-pdq> on October 13, 2021.

Sabel MS. Clinical manifestations, differential diagnosis, and clinical evaluation of a palpable breast mass. UpToDate. 2021. Accessed at <https://www.uptodate.com/contents/clinical-manifestations-differential-diagnosis-and-clinical-evaluation-of-a-palpable-breast-mass> on October 13, 2021.



Last Revised: January 14, 2022

# Breast Biopsy

- [Types of breast biopsies](#)

If breast [symptoms](#) or the results of an imaging test (such as a [mammogram](#)) suggest you might have breast cancer, you may need a breast biopsy. During a biopsy, a doctor removes small pieces of breast tissue from the suspicious area so they can be looked at in the lab to see if they contain cancer cells.

Needing a breast biopsy doesn't necessarily mean you have cancer. Most biopsy results are not cancer, but a biopsy is the only way to find out for sure.

## Types of breast biopsies

There are different kinds of breast biopsies. Some are done using a hollow needle, and some use an incision (cut in the skin). The type you have depends on a number of things, like:

- How suspicious the breast change looks or feels
- How big it is
- Where it is in the breast
- If there is more than one suspicious area
- Your overall health
- Your personal preferences

Most of the time, a needle biopsy (rather than a surgical biopsy) can be done. Ask your doctor which type of biopsy you will have and what you can expect during and after the procedure.

### [Fine needle aspiration \(FNA\)](#)

For a fine needle aspiration (FNA), a very thin, hollow needle attached to a syringe is used to withdraw (aspirate) a small amount of tissue or fluid from a suspicious area.

### [Core needle biopsy](#)

A core needle biopsy (CNB) uses a larger hollow needle to sample breast changes felt

by the doctor or seen on an ultrasound, mammogram, or MRI. This is often the preferred type of biopsy if breast cancer is suspected.

### [Surgical \(open\) biopsy](#)

In rare cases, surgery is needed to remove all or part of the lump for testing. This is called a surgical or open biopsy. Most often, the surgeon removes the entire mass or abnormal area as well as a surrounding margin of normal breast tissue.

### [Lymph node biopsy](#) <sup>1</sup>

This type of biopsy might be done to check the lymph nodes under the arm for cancer spread. This might be done at the same time as a biopsy of the breast tumor, or when the breast tumor is removed during surgery. Checking the lymph nodes can be done by core needle biopsy, or with a sentinel lymph node biopsy (SLNB) and/or an axillary lymph node dissection.

Regardless of which type of biopsy you have, the biopsy samples will be sent to a lab where a doctor called a *pathologist* will look at them. It typically will take at least a few days for you to find out the results.

### [Questions to Ask Before a Breast Biopsy](#)

It's important to ask questions if there's anything you're not sure about. Here you can find a detailed list of questions to ask your doctor before getting a breast biopsy.

If the doctor doesn't think you need a biopsy, but you still feel there's something wrong with your breast, follow your instincts. Don't be afraid to talk to the doctor about this or go to another doctor for a [second opinion](#)<sup>2</sup>. If possible, try to see someone who specializes in breast health to discuss your concerns. A biopsy is the only sure way to diagnose breast cancer.

## Hyperlinks

1. [www.cancer.org/cancer/types/breast-cancer/treatment/surgery-for-breast-cancer/lymph-node-surgery-for-breast-cancer.html](http://www.cancer.org/cancer/types/breast-cancer/treatment/surgery-for-breast-cancer/lymph-node-surgery-for-breast-cancer.html)
2. [www.cancer.org/cancer/managing-cancer/finding-care/seeking-a-second-opinion.html](http://www.cancer.org/cancer/managing-cancer/finding-care/seeking-a-second-opinion.html)

Last Revised: January 14, 2022

# Fine Needle Aspiration (FNA) of the Breast

- [What is an FNA of the breast?](#)
- [What should you expect if you have an FNA?](#)
- [What does an FNA show?](#)

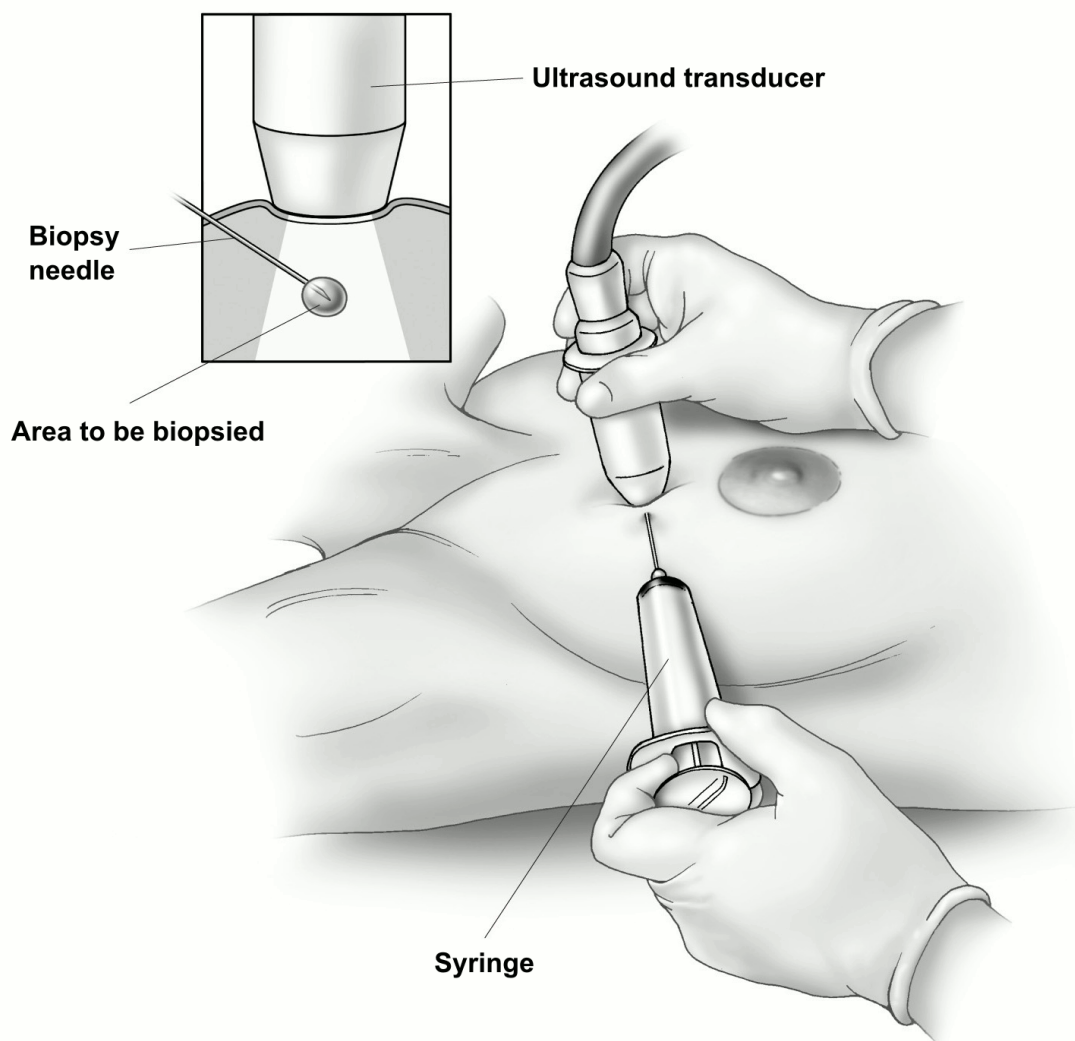
During a fine needle aspiration (FNA), a small amount of breast tissue or fluid is removed from a suspicious area with a thin, hollow needle and checked for cancer cells. This type of biopsy is sometimes an option if other tests show you might have breast cancer (although a [core needle biopsy](#) is often preferred). It might also be used in other situations.

## What is an FNA of the breast?

In an FNA, the doctor uses a very thin, hollow needle attached to a syringe to withdraw (aspirate) a small amount of breast tissue or fluid from a suspicious area.

FNA is most often done if the suspicious area is likely to be a fluid-filled sac (a [cyst](#)<sup>1</sup>). By removing fluid, the FNA can often help relieve pain from the cyst. FNA can also be helpful if the doctor is unsure if an area seen on an imaging test is a small cyst or a solid mass.

If the area to be biopsied can be felt, the needle can be guided into it while the doctor is feeling it.



© Sam and Amy Collins

## Fine needle aspiration using ultrasound

If the lump can't be felt easily, the doctor might watch the needle on an [ultrasound](#) screen as it moves toward and into the area. This is called an **ultrasound-guided FNA**.

If an FNA is done to test a suspicious area in the breast, the sample is then checked for cancer cells. One drawback of FNA is that it only removes a small amount of tissue and cells, so the sample usually needs to be checked right away under a microscope to make sure more samples don't need to be taken.

## What should you expect if you have an FNA?

## During an FNA

An FNA is an outpatient procedure most often done in the doctor's office. Your doctor might use a numbing medicine (called a *local anesthetic*), but it's not needed in all cases. This is because the needle used for the biopsy is so thin that getting an anesthetic might hurt more than the biopsy itself.

You'll lie on your back for the FNA, and you will have to be still while it's being done.

If ultrasound is used, you may feel some pressure from the ultrasound wand and as the needle is put in. Once the needle is in the right place, the doctor will use the syringe to pull out a small amount of tissue and/or fluid. This might be repeated a few times. Once the procedure is done, the area is covered with a sterile dressing or bandage.

Getting each biopsy sample usually takes about 15 seconds. The entire procedure from start to finish generally takes around 20 to 30 minutes if ultrasound is used.

## After an FNA

Your doctor or nurse will tell you how to care for the area where the biopsy was done and what you can and can't do while it heals. You might be told to limit strenuous activity for a day or so, but you should be able to go back to your usual activities after that.

Biopsies can sometimes cause bleeding, bruising, or swelling. This can make it seem like a breast lump is larger after the biopsy. Most often, this is nothing to worry about, and the bruising and swelling will go away over time. Your doctor or nurse will give you instructions on what to watch for and when you should call the office.

## What does an FNA show?

A doctor called a *pathologist* will look at the biopsy tissue or fluid to find out if there are cancer cells in it.

The main advantages of FNA are that it is fairly quick, it often doesn't require anesthesia, and the skin doesn't have to be cut, so no stitches are needed and there is usually no scar. Also, in some cases it's possible to get the results the same day.

However, an FNA can sometimes miss a cancer if the needle does not go into the cancer cells, or if it doesn't remove enough cells. Even if an FNA does find cancer, it might not remove enough cancer cells to do some of the other lab tests that are

needed.

If the results of the FNA biopsy do not give a clear diagnosis, or if your doctor still has concerns, you might need a more extensive type of biopsy, such as a [core needle biopsy](#) or a [surgical \(open\) biopsy](#).

## Hyperlinks

1. [www.cancer.org/cancer/types/breast-cancer/non-cancerous-breast-conditions/fibrosis-and-simple-cysts-in-the-breast.html](http://www.cancer.org/cancer/types/breast-cancer/non-cancerous-breast-conditions/fibrosis-and-simple-cysts-in-the-breast.html)

## References

Joe BN, Esserman LJ. Breast Biopsy. 2021. UpToDate. Accessed at [www.uptodate.com/contents/breast-biopsy](http://www.uptodate.com/contents/breast-biopsy) on October 14, 2021.

Radiological Society of North America. Ultrasound-Guided Breast Biopsy. 2021. Accessed at <https://www.radiologyinfo.org/en/info/breastbius> on October 14, 2021.

Last Revised: January 14, 2022

---

# Core Needle Biopsy of the Breast

- [What is a core needle biopsy?](#)
- [What should you expect if you have a CNB?](#)
- [Types of image-guided core needle biopsies](#)
- [What does a CNB show?](#)

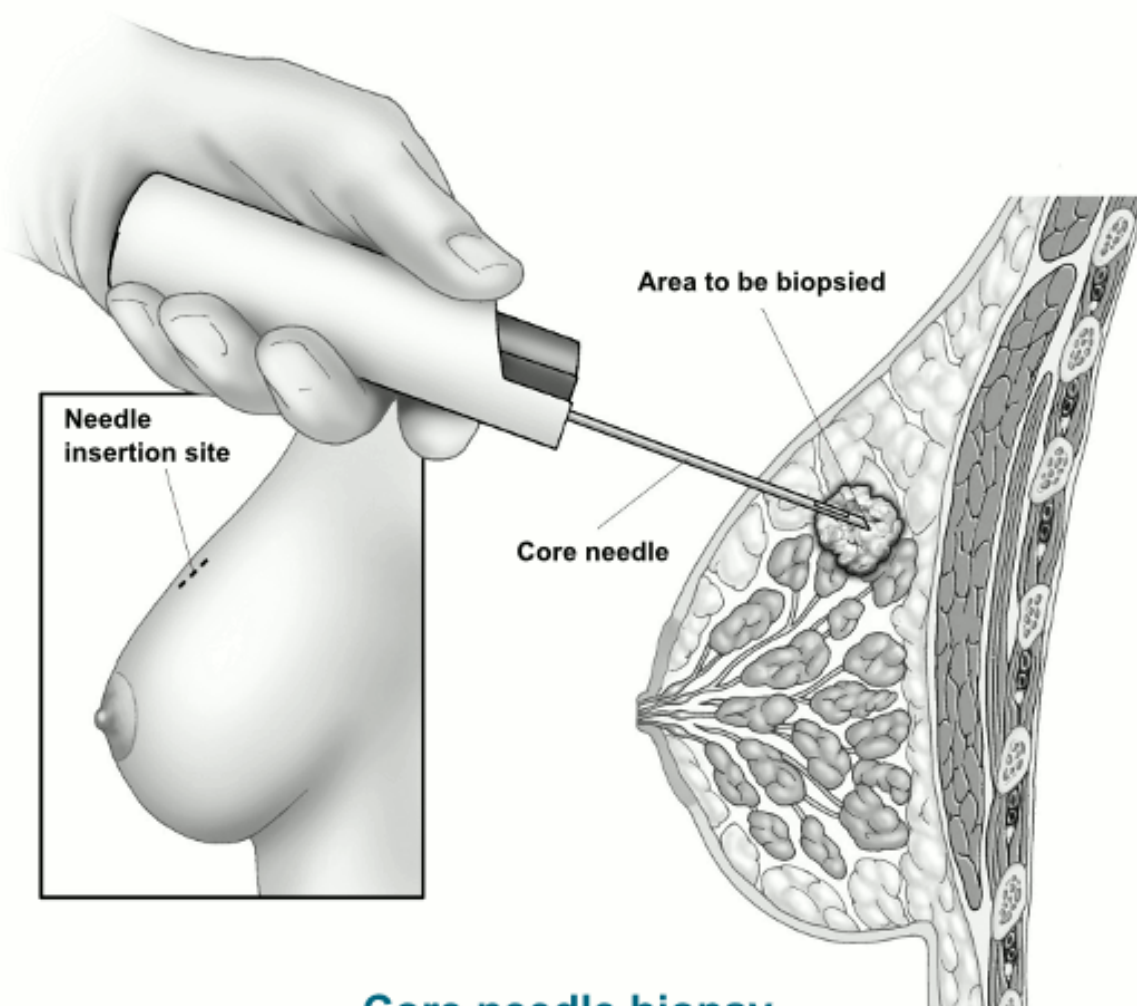
If exams or imaging tests show you might have breast cancer, your doctor might refer you for a core needle biopsy (CNB) to help find out for sure. This is often the preferred type of biopsy if breast cancer is suspected, because it removes more breast tissue than a [fine needle aspiration \(FNA\)](#), but it doesn't require [surgery](#).

During this procedure, the doctor uses a hollow needle to take out pieces of breast tissue from the area of concern. This can be done with the doctor either feeling the area or while using an imaging test to guide the needle.

### **What is a core needle biopsy?**

For a CNB, the doctor uses a hollow needle to take out pieces of breast tissue from a suspicious area the doctor has felt on exam or has seen on an imaging test. The needle may be attached to a spring-loaded tool that moves the needle in and out of the tissue quickly, or it may be attached to a suction device that helps pull breast tissue into the needle (known as a **vacuum-assisted core biopsy**).

A small cylinder (core) of tissue is taken out in the needle. Several cores are often removed.



## Core needle biopsy

The doctor might put the needle into the abnormal area by feeling the lump. But usually some type of imaging test is used to guide the needle into the right place. Some of the imaging tests a doctor may use include:

- [Mammogram](#) (or [breast tomosynthesis](#)) (known as a *stereotactic biopsy*)
- [Ultrasound](#)
- [MRI](#)

The type of imaging test used to guide the biopsy depends on which test can best see the abnormal area, as well as which is most comfortable for the patient.

## What should you expect if you have a CNB?



## During the CNB

A CNB is most often done as an outpatient procedure, such as in a doctor's office. The procedure itself is usually fairly quick, though it may take more time if imaging tests are needed or if one of the special types of CNB described below is used.

If your biopsy is done using image guidance, you may be sitting up, lying flat or on your side, or lying face down on a special table with openings for your breasts to fit into. This depends on which type of imaging (mammography, ultrasound, or MRI) is done. You will have to be still while the biopsy is done.

For any type of CNB, a thin needle will be used first to put numbing medicine (local anesthesia) into the area to be biopsied. Sometimes a small cut (about ¼ inch) is then made in the breast. The biopsy needle is put into the breast tissue through this cut to remove the tissue sample. You might feel pressure as the needle goes in. Again, an imaging test may be used to guide the needle to the right spot.

Typically, a tiny **tissue marker** (also called a **clip**) is put into the area where the biopsy is done. This marker will show up on mammograms or other imaging tests so the exact area can be located for further treatment (if needed) or follow up. You can't feel or see the marker. It can stay in place and is safe during MRIs, and it will not set off metal detectors.

Once the tissue is removed, the needle is taken out. Stitches aren't usually needed, but pressure may be applied for a short time to help limit bleeding. The area is then covered with a sterile dressing.

For more on what it's like to have each type of CNB, see "Types of image-guided core needle biopsies" below.

## After the CNB

You might be told to limit strenuous activity for a day or so, but you should be able to go back to your usual activities after that. Your doctor or nurse will give you instructions on this.

A CNB can cause some bleeding, bruising, or swelling. This can make it seem like the breast lump is larger after the biopsy. Most often, this is nothing to worry about, and any bruising or swelling will go away over time. Your doctor or nurse will tell you how to care for the biopsy site and when you might need to contact them if you're having any issues. A CNB usually doesn't leave a scar.

## Types of image-guided core needle biopsies

There are 3 main types of image-guided biopsies:

- Stereotactic (mammogram- or tomosynthesis-guided)
- Ultrasound-guided
- MRI-guided

The type of image-guided biopsy that is best for you will depend on which type of imaging test will show the abnormal area best, as well as your comfort.

### **Stereotactic (mammogram- or tomosynthesis-guided) core needle biopsy**

For this procedure, a doctor uses mammogram pictures taken from different angles to pinpoint the biopsy site. A computer analyzes the breast x-rays and shows where the needle tip needs to go in the abnormal area. This type of biopsy is often used to check suspicious [microcalcifications](#) (tiny calcium deposits) or small masses or other abnormal areas that can't be seen clearly on an ultrasound.

You may be sitting up, lying on your side, or lying on your belly with your breast hanging through a hole in the table for this procedure.

The breast will be positioned in the mammography machine and compressed, and an image will be taken to make sure the area in question can still be seen. The breast is then cleaned, and numbing medicine (local anesthesia) is given. The biopsy device is placed into the breast, and more images are taken to confirm that the device is in the correct spot to take samples. Several biopsy samples are then taken.

Afterwards, the device is removed from the breast, and a biopsy marker (clip) is placed in the area. Another mammogram is then done to confirm the marker is in the right place.

### **Ultrasound-guided core needle biopsy**

For this procedure, a doctor uses [breast ultrasound](#) to view the area that needs to be biopsied. Typically this is done while you are lying down or slightly on your side, with your arm above your head.

An ultrasound is done first to view the area. Then the skin is cleaned and numbing medicine (local anesthesia) is injected. Ultrasound is then used to guide the needle into

the correct area. You might feel pressure as the needle goes in. Several biopsy samples are usually taken.

A biopsy marker (clip) is placed in the area of the biopsy. Most often, a mammogram is done after the biopsy to confirm the clip is in the right place.

### **MRI-guided core needle biopsy**

For this procedure, a doctor uses [breast MRI](#) to locate and biopsy the suspicious area. This is most often done when something is seen on a breast MRI that is unlikely to be seen on mammogram or ultrasound. As with a breast MRI, you will be asked to lie on your belly on the MRI table with your arms above your head. However, the breast will be compressed during the procedure.

The table will slide into the MRI scanner and images will be taken. Then you'll be given contrast through an IV line (which can help make the abnormal area easier to see), and more images will be taken.

Once the suspicious area has been located, the skin is cleaned and numbing medicine (local anesthesia) is injected into the area. The biopsy device is then gently inserted into the breast. It's normal to feel pressure while this is being done.

More MRI images will then be taken to confirm to that the device is in the correct spot to take samples. Several biopsy samples are then taken, and the device is removed from the breast.

A biopsy marker (clip) is then placed in the area of the biopsy. Most often, a mammogram is done after the biopsy to confirm the clip is in the right place.

### **What does a CNB show?**

A doctor called a *pathologist* will look at the biopsy tissue and/or fluid to check if there are cancer cells in it. A CNB is likely to clearly show if cancer is present (and often provides enough of a sample if other lab tests are needed), but it can still miss some cancers.

Ask your doctor when you can expect to get the results of your biopsy. If the results of the CNB do not give a clear diagnosis, or if your doctor still has concerns, you might need to have a second CNB or a more extensive type of biopsy, such as a [surgical \(open\) biopsy](#).

## References

Joe BN, Esserman LJ. Breast Biopsy. 2021. UpToDate. Accessed at [www.uptodate.com/contents/breast-biopsy](http://www.uptodate.com/contents/breast-biopsy) on October 14, 2021.

Radiological Society of North America. Stereotactic Breast Biopsy. 2021. Accessed at <https://www.radiologyinfo.org/en/info/breastbixr> on October 14, 2021.

Radiological Society of North America. Ultrasound-Guided Breast Biopsy. 2021. Accessed at <https://www.radiologyinfo.org/en/info/breastbius> on October 14, 2021.

Sung JS, Comstock CE. Chapter 15: Image-Guided Biopsy of Nonpalpable Breast Lesions. In: Harris JR, Lippman ME, Morrow M, Osborne CK, eds. *Diseases of the Breast*. 5th ed. Philadelphia, Pa: Lippincott Williams & Wilkins; 2014.

Last Revised: January 14, 2022

# Surgical Breast Biopsy

- [What is a surgical biopsy?](#)
- [What to expect if you have a surgical biopsy](#)
- [What does a surgical biopsy show?](#)

If exams or imaging tests show you might have breast cancer, your doctor may refer you for a breast biopsy to help find out for sure. Most often this will be a [core needle biopsy \(CNB\)](#) or a [fine needle aspiration \(FNA\)](#). But in some situations, such as if the results of a needle biopsy aren't clear, you might need a surgical biopsy (sometimes called an **open biopsy**).

## What is a surgical biopsy?

For this type of biopsy, surgery is used to remove all or part of a suspicious area so it can be checked for cancer cells.

There are 2 types of surgical biopsies:

- An **incisional biopsy** removes only part of the abnormal area.

- An **excisional biopsy** removes the entire tumor or abnormal area. An edge (margin) of normal breast tissue around the tumor may be removed as well, depending on the reason for the biopsy.

## Preoperative localization to guide surgical biopsy

If the change in your breast can be felt, the surgeon can do the biopsy using their sense of touch as a guide.

But if the change can't be felt and/or is hard to find, an imaging test such as a [mammogram](#), [ultrasound](#), or [MRI](#) may be done before the surgery to help place a wire or other localizing device (such as a radioactive or magnetic seed, or a radiofrequency reflector) into the suspicious area. This can help guide the surgeon the right spot. This is called **preoperative localization**.

For **wire localization**, your breast is numbed, and an imaging test is used to guide a thin, hollow needle into the abnormal area. Once the tip of the needle is in the right spot, a thin wire is put in through the center of the needle. A small hook at the end of the wire keeps it in place, while the other end of the wire remains outside of the breast. The needle is then taken out. You then go to the operating room with the wire in your breast. The surgeon uses the wire as a guide to the area to be removed. When this method is used, it is done the same day as your surgery.

In **newer methods of localization**, a localizing device is put into the suspicious area before the day of your surgery, so you don't have to have it done the morning of your operation. Radioactive or magnetic seeds (tiny pellets that give off a very small amounts of radiation or that create small magnetic fields) or radiofrequency reflectors (small devices that give off a signal that can be picked by a device held over the breast) can be placed completely inside the breast (unlike the wire used for localization). Your surgeon can then find the suspicious area by using a handheld detector in the operating room.

## What to expect if you have a surgical biopsy

### During a surgical biopsy

Rarely, a surgical biopsy might be done in the doctor's office. But most often it's done in a hospital's outpatient department or a surgical center. You are typically given local anesthesia (numbing medicine), along with intravenous (IV) sedation to make you

drowsy. Another option is to have the biopsy done under general anesthesia (where you're given medicine to put you in a deep sleep and not feel pain).

The skin of the breast is cut, and the doctor removes the suspicious area. You will likely need stitches after a surgical biopsy, and pressure may be applied for a short time to help limit bleeding. The area is then covered with a sterile dressing.

### **After a surgical biopsy**

The biopsy can cause bleeding, bruising, or swelling. This can make it seem like the breast is larger after the biopsy. Most often, this is nothing to worry about, and the bruising and swelling will go away over time. Your doctor or nurse will tell you how to care for the biopsy site, how much (and for how long) you might need to limit your activities, and when you might need to contact them if you're having any issues.

A surgical biopsy may leave a scar. You might also notice a change in the shape of your breast, depending on how much breast tissue is removed.

### **What does a surgical biopsy show?**

A doctor called a *pathologist* will look at the biopsy tissue under a microscope to check it for cancer cells.

Ask your doctor when you can expect to get the results of your biopsy. The next steps will depend on the biopsy results.

If no cancer cells are found in the biopsy, your doctor will talk to you about whether any other tests are needed, as well as when you need to have your next mammogram and any other follow-up visits.

If breast cancer is found, other lab tests might be done on the tissue to learn more about the cancer and how best to treat it. Your doctor will talk to you about these tests and about what the next steps will be. You might need to see other doctors, too. For more on this, see [Understanding a Breast Cancer Diagnosis](#)<sup>1</sup>.

## **Hyperlinks**

1. [www.cancer.org/cancer/types/breast-cancer/understanding-a-breast-cancer-](http://www.cancer.org/cancer/types/breast-cancer/understanding-a-breast-cancer-)

[diagnosis.html](#)

## References

Chagpar AB. Techniques to reduce positive margins in breast-conserving surgery. 2021. UpToDate. Accessed at [www.uptodate.com/contents/techniques-to-reduce-positive-margins-in-breast-conserving-surgery](http://www.uptodate.com/contents/techniques-to-reduce-positive-margins-in-breast-conserving-surgery) on October 14, 2021.

Joe BN, Esserman LJ. Breast Biopsy. 2021. UpToDate. Accessed at [www.uptodate.com/contents/breast-biopsy](http://www.uptodate.com/contents/breast-biopsy) on October 14, 2021.

Last Revised: January 14, 2022

---

# Questions to Ask Before a Breast Biopsy

There are different types of breast biopsies. It's important to understand the type of biopsy you'll have and what you can expect during and after the biopsy.

Here are some questions you might want to ask before having a breast biopsy:

- What [type of biopsy](#) do you think I need? Why?
- Will the size of my breast affect the way the biopsy is done?
- Where will the biopsy be done?
- What exactly will you do?
- How much breast tissue will you remove?
- How long will it take?
- Will I be awake or asleep during the biopsy?
- Will the biopsy area be numbed?
- If you can't feel the abnormal area in my breast, how will you find it?
- If you are using a guide wire to help find the abnormal area, how will you make sure

- it's in the right place (with ultrasound or a mammogram)?
- Will I need someone to help me get home afterward?
  - Will I have a hole there afterward? Will it show?
  - Will my breast have a different shape or look different afterward?
  - Will you put a clip or marker in my breast? If so, what will happen to it?
  - Will I have a scar? Where will it be? What will it look like?
  - Will I have bruising or changes in the color of my skin? If so, how long will it last?
  - Will I be sore? If so, how long will it last?
  - Might I have any other types of problems after the biopsy? Are there any I'd need to call your office about?
  - When can I take off the bandage?
  - When can I take a shower or bath?
  - Will I have stitches? Will they dissolve or will I need to come back to the office and have them removed?
  - When can I go back to work? How will I feel when I do?
  - Do I need to limit activities like lifting things or raising my arm? If so, for how long?
  - How soon will we know the biopsy results?
  - Should I call you or will you call me with the results?
  - Will you or someone else explain the biopsy results to me?

Last Revised: January 14, 2022

---

## Finding Breast Cancer During Pregnancy

- [How common is breast cancer during pregnancy?](#)
- [Breast cancers can be harder to find when you're pregnant](#)
- [What to look for](#)
- [Are mammograms and other imaging tests safe during pregnancy?](#)
- [Breast biopsy during pregnancy](#)
- [Imaging tests to stage breast cancer](#)
- [Treating the cancer](#)
- [Can breast cancer spread to the baby?](#)



Breast cancer during pregnancy isn't common. But if you find a lump or notice any changes in your breasts that concern you, tell your doctor or nurse right away. There are a variety of tests a pregnant woman can have if breast cancer is suspected. And there are options for [treating breast cancer if you are pregnant](#)<sup>1</sup>.

If you are pregnant and breast cancer is found, it may be called **gestational breast cancer** or **pregnancy-associated breast cancer (PABC)**.

## How common is breast cancer during pregnancy?

Breast cancer is found in about 1 in every 3,000 pregnant women. It is the most common type of cancer found during pregnancy.

## Breast cancers can be harder to find when you're pregnant

Changes in hormone levels during pregnancy cause the breasts to change. The breasts may become larger, lumpy, and/or tender. This can make it harder for you or your doctor to notice a lump caused by cancer until it gets quite large.

Another reason it may be hard to find breast cancers early during pregnancy is that many women put off breast cancer screening with [mammograms](#) until after the pregnancy. Even when women do get mammograms, pregnancy and breastfeeding can make breast tissue denser, which can make it harder to see an early cancer on a mammogram.

Because of these challenges, when a pregnant woman develops breast cancer, it's often diagnosed at a later stage than it usually is in women who are not pregnant. For example, it's more likely to have already spread to lymph nodes.

## What to look for

If you find a [lump or other changes in your breasts](#) that concern you, don't ignore them. Tell your doctor or nurse right away. Any suspicious breast changes should be checked out or even biopsied (see below) before assuming they are a normal response to pregnancy.

Along with a clinical breast exam, several types of imaging tests can be used to look for breast abnormalities, if needed. Typically a [breast ultrasound](#) and/or [mammogram](#) can be done. A [breast biopsy](#) (removing a piece of the abnormal area to check it for cancer cells) is often another option, especially if imaging tests show a suspicious finding. (See

below.)

## Are mammograms and other imaging tests safe during pregnancy?

A main concern with any imaging test during pregnancy is whether it exposes the developing fetus to radiation, which could be harmful, especially during the first trimester.

**Mammograms** can find most breast cancers that start when a woman is pregnant, and it's generally thought to be safe to have a mammogram during pregnancy. The amount of radiation needed for a mammogram is small, and the radiation is focused on the breasts, so most of it doesn't reach other parts of the body. For extra protection, a lead shield is placed over the lower part of the belly to help keep radiation from reaching the womb. Still, small amounts of radiation might reach the fetus, and scientists can't be certain about the effects of even a very small dose of radiation on an unborn baby.

**Ultrasound** exams of the breast do not use radiation and are thought to be safe during pregnancy. This is typically an easy test to have, so it's often the first test used to evaluate a change in the breast (such as a lump) during pregnancy.

Other tests, such as **PET scans**, **bone scans**, and **computed tomography (CT) scans** are more likely to expose the fetus to radiation (see below).

**Magnetic resonance imaging (MRI)** does not use radiation. However, **breast MRIs** typically require that a contrast material called *gadolinium* is injected into the blood in order to get useful images. This contrast can cross the placenta (the organ that connects the mother to the fetus) and has been linked with fetal abnormalities in lab animals. Because of this, doctors typically don't recommend breast MRI during pregnancy.

## Breast biopsy during pregnancy

If a new breast lump or abnormal imaging test result raises concerns about a breast change possibly being cancer, a **biopsy** is typically done. During a biopsy, small pieces of breast tissue are taken from the area of concern.

The most common breast biopsy technique is a **core needle biopsy**, which uses a hollow needle to remove the pieces of breast tissue. This is usually done as an outpatient procedure, even if you're pregnant. Most often, numbing medicine (local anesthesia) is used to numb just the area of the breast where the biopsy will be done. This causes little risk to the fetus.

If a core needle biopsy doesn't give a clear answer, a [surgical biopsy](#) is typically the next step. For this type of biopsy, a larger piece of breast tissue is removed through a small cut (incision) in the breast. Surgical biopsies are often done under general anesthesia (where you are given medicine to put you into a deep sleep), which carries a small risk to the fetus.

## Imaging tests to stage breast cancer

If breast cancer is found, you might need other tests to find out if cancer cells have spread within the breast or to other parts of the body. This process is called [staging](#)<sup>2</sup>. Different staging tests may be needed, depending on your situation.

As noted above, **ultrasound** scans do not use radiation and are safe during pregnancy.

**Chest x-rays** are sometimes needed to help make treatment decisions. They use a small amount of radiation to create the images. They're generally thought to be safe to have when you're pregnant, as long as your belly is shielded.

Other tests, such as **PET scans**, **bone scans**, and **computed tomography (CT) scans** are more likely to expose the fetus to radiation. These tests are not often needed to stage breast cancer, especially if the cancer is thought to be just in the breast. If one of these tests is needed, doctors might be able to make adjustments to limit the amount of radiation exposure to the fetus.

## Treating the cancer

The treatment of breast cancer in pregnant women is typically similar to that used for non-pregnant women, especially for early-stage disease, although some adjustments might be needed to help protect the fetus. Learn more in [Treating Breast Cancer During Pregnancy](#)<sup>3</sup>.

## Can breast cancer spread to the baby?

Breast cancer has never been found to spread from the mother to the fetus. But in a few rare cases, the cancer has reached the placenta (the organ that connects the mother to the fetus). This could affect the amount of nutrition the fetus gets from the mother.

For answers to some common questions about pregnancy *after* having had breast cancer, see [Pregnancy After Breast Cancer](#)<sup>4</sup>.

## Hyperlinks

1. [www.cancer.org/cancer/types/breast-cancer/treatment/treating-breast-cancer-during-pregnancy.html](http://www.cancer.org/cancer/types/breast-cancer/treatment/treating-breast-cancer-during-pregnancy.html)
2. [www.cancer.org/cancer/diagnosis-staging/staging.html](http://www.cancer.org/cancer/diagnosis-staging/staging.html)
3. [www.cancer.org/cancer/types/breast-cancer/treatment/treating-breast-cancer-during-pregnancy.html](http://www.cancer.org/cancer/types/breast-cancer/treatment/treating-breast-cancer-during-pregnancy.html)
4. [www.cancer.org/cancer/types/breast-cancer/living-as-a-breast-cancer-survivor/pregnancy-after-breast-cancer.html](http://www.cancer.org/cancer/types/breast-cancer/living-as-a-breast-cancer-survivor/pregnancy-after-breast-cancer.html)

## References

Litton JK. Gestational breast cancer: Epidemiology and diagnosis. UpToDate. 2021. Accessed at <https://www.uptodate.com/contents/gestational-breast-cancer-epidemiology-and-diagnosis> on October 15, 2021.

Litton JK, Theriault RL. Chapter 65: Breast Cancer During Pregnancy and Subsequent Pregnancy in Breast Cancer Survivors. In: Harris JR, Lippman ME, Morrow M, Osborne CK, eds. *Diseases of the Breast*. 5th ed. Philadelphia, Pa: Lippincott Williams & Wilkins; 2014.

National Cancer Institute. Breast Cancer Treatment During Pregnancy (PDQ). 2019. Accessed at <https://www.cancer.gov/types/breast/hp/pregnancy-breast-treatment-pdq> on October 15, 2021.

National Comprehensive Cancer Network. NCCN Clinical Practice Guidelines in Oncology. Breast Cancer Screening and Diagnosis. Version 1.2021. Accessed at [https://www.nccn.org/professionals/physician\\_gls/pdf/breast-screening.pdf](https://www.nccn.org/professionals/physician_gls/pdf/breast-screening.pdf) on December 1, 2021.

Sechopoulos I, Suryanarayanan S, Vedantham S, D'Orsi CJ, Karellas A. Radiation dose to organs and tissues from mammography: Monte Carlo and phantom study. *Radiology*. 2008;246(2):434-443.

Taylor D, Lazberger J, Ives A, Wylie E, Saunders C. Reducing delay in the diagnosis of pregnancy-associated breast cancer: How imaging can help us. *J Med Imaging Radiat Oncol*. 2011;55(1):33-42.

Venkataraman S, Slanetz PJ, Lee CI. Breast imaging for cancer screening:

Mammography and ultrasonography. UpToDate. 2021. Accessed at <https://www.uptodate.com/contents/breast-imaging-for-cancer-screening-mammography-and-ultrasonography> on October 15, 2021.

Viswanathan S, Ramaswamy B. Pregnancy-associated breast cancer. *Clin Obstet Gynecol*. 2011;54(4):546-555.

Yang WT, Dryden MJ, Gwyn K, et al. Imaging of breast cancer diagnosed and treated with chemotherapy during pregnancy. *Radiology*. 2006;239(1):52-60.

Last Revised: January 14, 2022

### Written by

The American Cancer Society medical and editorial content team  
(<https://www.cancer.org/cancer/acs-medical-content-and-news-staff.html>)

Our team is made up of doctors and oncology certified nurses with deep knowledge of cancer care as well as journalists, editors, and translators with extensive experience in medical writing.

American Cancer Society medical information is copyrighted material. For reprint requests, please see our Content Usage Policy ([www.cancer.org/about-us/policies/content-usage.html](http://www.cancer.org/about-us/policies/content-usage.html)).

**cancer.org | 1.800.227.2345**